

Victorian Integrated Cancer Services

Piloting a New Radiological Synoptic Report for Classifying and Documenting Resectability in Pancreatic Cancer

A partnership between the Southern Melbourne, and North Eastern Melbourne Integrated Cancer Service

2021



Contents

Abbreviations	2
Acknowledgements	2
Authorship	2
Key Messages	3
Executive Summary	4
Background	8
• Aims	8
• Objectives.....	8
• Governance, engagement, and communication	8
• Methodology (including scope).....	9
Program of Work	21
• Measurables.....	21
• Pilot results.....	22
• Key Lessons learned.....	26
- Enablers.....	26
- Challenges	26
- Lessons learned.....	27
Outputs and Outcomes	29
• Project outputs	29
• Current Outcomes	29
• Possible Future Outcomes	29
Recommendations	30
Appendices	31
References.....	41

Abbreviations

Abbreviation	Definition
PDAC	Pancreatic ductal adenocarcinoma
MDM	Multidisciplinary meeting
ICS	Integrated Cancer Service
NEMICS	North Eastern Melbourne Integrated Cancer Service
SMICS	Southern Melbourne Integrated Cancer Service
UGICR	Upper Gastrointestinal Cancer Registry
HPB	Hepatopancreatobiliary
RIS	Radiology Information System
PACS	Picture archiving and communication <i>system</i>
ARGANZ	Abdominal Radiology Group of Australia and New Zealand
EMR	Electronic medical record, also referred to as medical record throughout
REDCap	Research Electronic Data Capture
CT	Computed Tomography
HS	Health Service
HIS	Health Information Service
VCR	Victorian Cancer Registry

Acknowledgements

The Project Team would like to thank and acknowledge the following contributors to this project

Project Chair and Coordinating Principal Investigator: Associate Professor Charles Pilgrim, HPB surgeon, The Alfred Hospital and Deputy Chair: Associate Professor Andrew Haydon, oncologist The Alfred Hospital.

Dr Mark Goodwin, radiologist and Site Principal Investigator at Austin Health and Associate Professor Samantha Ellis, radiologist and Site Principal Investigator at The Alfred Hospital, the two pilot sites; members of the Project Steering Group and Working Group together with the Data Team at the Upper Gastrointestinal Registry led by Professor John Zalcborg, Head, Cancer Research Program, Public Health and Preventive Medicine, Monash University.

For the full list of project participants refer to Appendix A.

Authorship

This report was prepared by Anna Maciejewska, Senior Project Manager, Southern Melbourne Integrated Cancer Service (SMICS), in partnership with Nadia Ayres, OCP Manager, North Eastern Melbourne Integrated Cancer Service (NEMICS).

Key messages

- The new synoptic report for pancreatic CT scans adds real value to radiological assessment and surgical decision making by facilitating consistent and accurate classification and documentation of anatomical resectability in pancreatic cancer. It is also quick and easy to use.
- Collecting pancreatic cancer radiology synoptic report data centrally supports statewide monitoring of cancer care and promotes research into patient outcomes, potentially reducing variations in care
- Hospital based radiology information systems (RIS) are the ideal platform for the storage of all radiology information including the radiological synoptic report for pancreatic cancer, however RIS are neither a uniform software solution nor suitable for housing externally generated reporting data.
- It was identified that 17% of scans presented at MDM for this pilot project were of an inadequate quality, to enable a specialist radiologist to perform any form of resectability assessment. 75% of these inadequate quality scans were from external providers.
- The proportion of unregistered patients (i.e. patients not previously known to that hospital network) presented for MDM review as part of this pilot was found to be 32%. This incidental finding means that a significant group of patients will not have their synoptic report documented in the electronic medical record at health services or their resectability status noted in the MDM summary.
- Data has shown that 59% of imaging presented for radiology review for suspected pancreatic cancer originated from external radiology providers. There is a real need for an individual process that would consistently allow upload of the synoptic report of these external scans in the patient medical record.

Executive summary

The lack of documented and agreed common criteria to define surgical resectability in pancreatic cancer is a barrier to determining and comparing appropriate treatment for patients and may in part account for the known variations in care.

The pancreatic cancer resectability project was born out of a discussion by clinicians, on areas of deficiency in the data, presented at the Victorian Pancreatic Cancer Summit, in 2017.

After the summit, in a series of workshops, the importance of patients receiving effective systemic therapy was discussed. It was acknowledged that delivering chemotherapy prior to surgery for patients with borderline resectable pancreatic ductal adeno carcinoma (PDAC) was a promising new approach. Data tabled at the Summit also revealed inconsistencies in the delivery of chemotherapy for patients who underwent surgical resection.

A subsequent statewide audit to further investigate these findings confirmed that inconsistencies also existed in the classification of borderline resectable (BR) disease. Noting these important findings, clinicians agreed that a clear and consistent method to identify patients with borderline disease was needed to guide treatment sequencing appropriately and consistently. Discussion followed regarding the need to adopt a common set of guidelines to assess disease status, in particular surgical resectability in non-metastatic PDAC.

In response to the variation in care identified, two Integrated Cancer Services (ICS) SMICS and NEMICS, partnered to propose a project that would gather interested clinicians to agree a common set of governing guidelines and then lead a facilitated co-design process to create a synoptic radiological report template, testing its applicability in the clinical environment.

Four project aims were identified

1. Agreeing and adopting a common statewide definition of resectability to ensure consistent management of PDAC patients in Victoria.
2. Designing a new radiological synoptic report based on the agreed set of guidelines.
3. Piloting the new tool in two health service Hepatopancreatobiliary Multidisciplinary Meetings (HPB MDMs) to test the new tool, and
4. Documenting the resectability status on MDM outcome record and saving it along with the synoptic report to the medical record.

A Project Steering Committee and Working Group representing pancreatic surgery centres across the state was established. The Working Group agreed use of the 'International consensus on definition and criteria of borderline resectable pancreatic ductal carcinoma 2017' and these guidelines were unanimously accepted. However, the need to embed this into clinical practice remained.

A co-design approach was used to develop a structured or 'synoptic' reporting template to characterise anatomical resectability in pancreatic cancer. Working Group members, including radiologists, surgeons and medical oncologists, were involved in the clinical consultation to determine both the structure and requirements of a suitable reporting template.

The radiological synoptic report template contained sections for demographic details, mass characteristics, arterial and venous evaluation, and a conclusion and resectability status.

The Working Group members agreed that a research database, known as REDCap (Research Electronic Data Capture), could be used to capture the radiological data and provide a readily available and accessible online platform for the development of the report.

A draft version of the document was tabled with the Working Group and reviewed field by field. A prototype was subsequently tested on several patient cases at two pilot sites to provide further granular detail. The final template was accepted by the Working Group and tabled with the Directors of Radiology at both sites, ready for testing in a clinical pilot environment.

The International Guidelines 2017 classify anatomical resectability in pancreatic cancer using the following terms. This classification was applied to the new synoptic report.

- Resectable (R)
- Borderline resectable – venous involvement (BR-PV)
- Borderline resectable – arterial involvement (BR-A)
- Unresectable – locally advanced (UR-LA)
- Unresectable – metastatic (UR-M)

Early in the consultation, radiologists identified the need to ensure the reporting process developed was compatible for both internally and externally acquired imaging. It was recognised that externally acquired imaging forms a significant proportion of the overall number of CT images presented for radiological review in the setting of suspected pancreatic cancer and that the imaging did not follow the conventional radiological information pathway. Internally acquired hospital imaging, on the other hand, is standardly reported through in-house radiology information systems (RIS). As a result, it was deemed necessary to also produce the structured reporting template in a custom template format for use in the RIS environment.

Initial testing identified that the report required further refining to include dedicated fields to assist radiologists in determining the appropriateness of the imaging presented, and its suitability for use in the assessment of disease resectability.

In cases where the imaging presented for review was of a suitable standard, a *full* synoptic report could be completed. In cases where poor quality imaging was submitted, however, only a *partial* radiology report was issued. The partial report outlined the inadequacy of the imaging with reference to its appropriateness for use in assessing pancreatic and surrounding vessel anatomy.

The pilot project, conducted at Alfred Health and Austin Health, required radiologists assigned to HPB MDMs to review CT imaging presented for patients listed for discussion with suspected pancreatic cancer. Radiologists used the synoptic reporting tool to assess the CT images and uploaded their report to the medical record. Then, at the MDM, radiologists presented their findings and stated their concluding anatomical resectability status. The HPB MDM scribes were then asked to record these findings on the MDM outcome summary and uploaded this to the medical record.

The radiological synoptic report generated for internal scans in RIS is automatically uploaded to the patient electronic medical record (EMR) once completed. Upload of external synoptic reports presented more of a challenge.

As the REDCap reports are created on an external database, navigating secure health service firewalls to send and receive reports for upload to the EMR required individual solutions to be identified.

The participating clinicians, on both the Working and Steering Groups, recognised the opportunity of collecting data centrally and using this to monitor variation in care. It was also recognised that central collection would allow standardisation of the data.

The Upper Gastrointestinal Cancer Registry (UGICR) is a clinical quality registry, previously developed to monitor and report on quality-of-care information on patients diagnosed with UGI cancers. The Working Group recommended exploring the UGICR as a data warehouse for the pilot as it already collected data on pancreatic cancer resectability at pancreatic surgery sites nationally. Most importantly, the registry also collected data in REDCap.

A partnership between the resectability project and the UGICR was established. The partnership was seen as mutually beneficial as the project data would add value to the registry by providing reliable pancreatic cancer resectability data for future research and analysis, which is often reliant on the use of retrospective data. Simultaneously the registry would provide the secure REDCap platform, on which to build and collect the project data, leveraging existing governance and security frameworks.

Findings

To monitor uptake of the guidelines and measure progress in the clinical setting, data was collected as four distinct project measurables:

Project measure 1 Radiology report completed
A total of 95 radiological resectability synoptic reports were completed by radiologists at the two pilot sites.
Project measure 2 Resectability status determined
Overall, 83% of CTs presented for MDM review as part of the pilot study, were of an appropriate quality to support resectability assessment and therefore had a resectability status determined.
Project measure 3 Resectability status documented in MDM summary and uploaded to EMR
Overall, 80% of patients eligible for inclusion in this measure (those registered at the health service) had a record of their resectability status documented in their MDM summary and uploaded to the EMR.
Project measure 4 Radiology report uploaded to the EMR
Overall, 82% of registered patients in the pilot project had a copy of their radiology synoptic report uploaded and available for view on the hospital EMR.

Additionally, the data showed that overall, 59% of scans presented for radiology review for suspected pancreatic cancer originated from external providers highlighting the need to ensure a process exists for both imaging sources.

Importantly 17% of scans presented overall were of an inadequate quality to enable a specialist radiologist to perform any resectability assessment for the purposes of developing a multidisciplinary treatment plan. A further 25% of scans were of suboptimal quality, but at least of sufficient radiological detail to allow classification of the resectability status.

Overall, it was found that synoptic reporting facilitates both the classification and documentation of resectability in suspected pancreatic cancer. Synoptic reporting clearly needs to be compatible for both internal and external CTs and should support the upload of the completed reports to the hospital EMR.

Feedback received from clinicians surveyed regarding the pancreatic resectability pilot project showed that the reporting process implemented was received favourably by the radiologists and HPB MDM clinicians who took part. The project also clearly demonstrated that poor quality imaging hinders the ability to assess pancreatic resectability.

Recommendations

1. The new pancreatic cancer radiological synoptic report offers a quick, consistent and accurate way of classifying and documenting anatomical resectability in pancreatic patients. Post pilot clinician feedback confirms it is a valuable and useful tool for radiological assessment and surgical decision-making. It is recommended this report be implemented in all Victorian HPB MDMs that perform treatment planning for pancreatic cancer patients.
2. As synoptic reporting of pancreas CTs is a specialised skill, it should be carried out by experienced radiologists who review a high volume of pancreatic cancer imaging. It is recommended that the synoptic reporting tool be made available specifically to HPB MDMs responsible for treatment planning of pancreatic cancer patients.

3. Data from the new radiological synoptic report should be centrally collected and housed in REDCap (Research Electronic Data Capture) using the existing UGICR (UGI Cancer Registry) database to support statewide outcome monitoring to reduce variation in care, until such a time as the Victorian Cancer Registry (VCR) can perform this function.
4. Reporting of **internally** generated CTs should be completed on a RIS template, where available, to ensure the report is directly uploaded to the health service EMR.
5. Reviews of **externally** generated CTs for MDM will require a separate housing platform as these reports are currently not stored in RIS.
6. Patients should be registered with the Health Service prior to MDM discussion to enable upload of all clinical documents, such as synoptic reports and MDM summaries to the EMR.
7. MDM reviews of externally generated CTs that are documented using the new synoptic report, should be uploaded to the medical record with the MDM summary documentation.
8. Clear guidelines are needed to support radiologists when issuing a review report for MDM treatment planning purposes on a CT scan that was requested by, and completed for, another provider.
9. To allow completion of the synoptic report, specialist radiologists should be given sufficient notice prior to the MDM to review pancreatic CT imaging.
10. RANZCR (Royal Australian and New Zealand College of Radiology) endorsement of the pancreatic resectability synoptic report template should be pursued.
11. A wider roll out of synoptic reporting using the REDCap platform would require individual assessment of hospital IT capabilities to fully implement, as not all HS have uniform IT capabilities to allow direct send and upload of REDCap reports to EMR.
12. Any further expansion of the pancreatic resectability synoptic reporting project should be managed with a central oversight model and with the use of previously developed tools to ensure consistency.

Background

Aims

- Improve patient outcomes by agreeing a common standard statewide definition for resectability for pancreatic ductal adenocarcinoma, in this way ensuring consistent management of pancreatic cancer patients.
- Introduce a standard structured radiological reporting template across health services to enable a consistent presentation of resectability status at multidisciplinary meetings (MDM).

Objectives

- Engage key stakeholders and document agreement to a single statewide definition of resectability by 1 July 2020.
- Develop and test a standard structured radiological reporting template across two health services by 1 October 2021.
- Run a pilot of the developed structured reporting template in SMICS and NEMICS health services, (Alfred Health and Austin Health sites) from October 2020 to 30 September 2021.
- Evaluate pilot findings and disseminate to relevant stakeholders including the Department of Health by December 2021.

Governance, engagement, and communication

The work on the pancreatic cancer resectability project was undertaken by two Integrated Cancer Services, part of Victoria's cancer services improvement network made up of nine centres in the state. The role of these services is to build relationships between healthcare providers and other cancer care stakeholders to develop, implement and evaluate initiatives that improve the way Victoria's health services provide care and support.

The project was led by SMICS in partnership with NEMICS.

From the very beginning, the Project Team focussed on wide clinical engagement, communication, and collaboration with key stakeholders.

The Project Team also established a structured governance framework at the start of the project.

A Steering Group was established to maintain oversight of the initiative, with regular meetings held and formal updates provided during the length of the project cycle.

A Working Group consisting of interested radiologists, surgeons and medical oncologists representing key surgical pancreatic centres in the state, was similarly established to enable open discussion among disciplines in relation to the adoption of a common set of guidelines and development of a synoptic report. The project team also kept in regular contact with the two principal investigators at the two participating health service sites. *For the full membership of the two groups, list of meetings held, and written updates presented please refer to Appendix A.*

Initial engagement and consultation included meetings with the Chair of the Pancreatic Tumour Summit 2017. It was as part of the Working Group meetings during the 2017 summit that the need for a standardised definition for surgical resectability was identified as a critical need to improve treatment of pancreatic cancer.

The Project team also met and consulted with MDM Chairs of the HPB meetings at nominated pilot sites, the Directors of Radiology Departments at Alfred Health and Austin Health, together with relevant radiologists, surgeons and medical oncologists.

Other engagement included the Department of Health, the SMICS Governance Committee, the Abdominal Radiology Group Australia and New Zealand (ARGANZ), The Australasian Gastro-Intestinal Trials Group (AGITG), Australia and New Zealand Hepatic, Pancreatic and Biliary Association (ANZHPBA), and the Upper Gastrointestinal Cancer Registry (UGICR). A representative of the Purple Registry was included in the Working Group, and meetings were held with the Victorian Cancer Registry (VCR).

The Project Team also engaged with the broader pancreatic community. A dedicated project newsletter was developed, outlining the project aims and progress, and was regularly shared with over 90 clinicians in the state.

Other initiatives included the production of a dedicated video presentation, found at <https://www.youtube.com/watch?v=g-QuDQzfqGY> featured as part of the SMICS Annual Forum in 2020, which was attended by clinicians and project managers from across the cancer sector.

Three separate presentations were also produced for the Clinical Oncology Society of Australia, COSA 2021 meeting, showcasing the results at the two pilot sites.

The Project Team engaged with the two pilot site radiologist teams through dedicated presentations and training sessions. It also produced a training manual for use of the REDCap synoptic report located at the UGICR registry for both radiologists and surgeons.

Methodology

The pancreatic cancer resectability project was born out of a discussion by clinicians, on areas of deficiency in the statewide data, at the Victorian Pancreatic Cancer Summit, in 2017.

In a series of workshops, held after the summit, the importance of patients receiving effective systemic therapy was discussed. Despite treatment with curative intent, 23% of patients undergoing surgical resection for pancreatic cancer never received adjuvant systemic therapy. This was seen as a clinically significant deficiency and measures to improve the rate of systemic therapy delivered were discussed. It was acknowledged that delivering chemotherapy prior to surgery for patients with borderline resectable pancreatic ductal adenocarcinoma (PDAC) was a promising new approach.

However, a statewide audit confirmed inconsistencies in the classification of borderline resectable (BR) disease.

Therefore, the adoption of a common set of guidelines to clearly define what constitutes borderline resectable disease was identified as an important step in addressing this inconsistency.

In late 2018, SMICS in partnership with the NEMICS prioritised this variation in pancreatic cancer care as part of their work in the Pancreatic Cancer Optimal Care Pathway Implementation.

This methodology describes the pilot study, which aimed to agree a common standard statewide definition for resectability, and to subsequently develop a standard structured radiological reporting template to enable a consistent presentation of the radiological anatomical resectability status for pancreatic patients at MDM.

Before undertaking the study, the Project Team made the following assumptions regarding the pilot:

What was in scope	What was <u>out</u> of scope
<ul style="list-style-type: none"> ▪ The project would bring about agreement on the adoption of a single common radiological definition of pancreatic resectability, that is anatomical. ▪ The project would produce a surgically focussed synoptic radiological report that would assist surgeons to develop a treatment plan at MDM. ▪ All CTs (internally and externally acquired) presented for suspected pancreatic cancer review would be considered. ▪ The synoptic tool would be used specifically to report scans (both internal, unreported and external previously reported scans originating outside the health service) in alignment with an agreed definition of resectability status, for the purposes of the MDM meeting; Scans not available prior to the MDM for reporting, would still be included as this reflected real world processes. ▪ The pilot would be contained to two sites. ▪ The pilot would implement and test the newly developed synoptic report. ▪ The synoptic report's resectability finding would be tabled in the MDM summary report; and the report itself would have to be saved to the medical record. 	<ul style="list-style-type: none"> ▪ MRI or other imaging. ▪ what the surgeons chose to do with the content provided in the synoptic report. ▪ comparison of existing resectability guidelines, and the subsequent creation of a 'new' version.

- Broader clinical engagement would be sought despite it being a predominantly radiological project.

Two health services participated in the pilot, which commenced in October 2020 and ended on September 30, 2021.

- **Alfred Health** located in the **SMICS** catchment, and
- **Austin Health** located in the **NEMICS** catchment.

Each of these health services hosted a dedicated Hepatopancreatobiliary (HPB) multidisciplinary meeting (MDM) that discussed pancreatic cancer cases, held each week.

The overall study contained two key phases, as summarised below.

Pilot Study Phase 1
1. Initiate stakeholder consultation. Document Project Plan.
2. Engage and convene Steering Committee to oversee project delivery and agree plan.
3. Form Working Group to review existing guidelines and engage the wider clinical sector.
4. Review feedback and define agreed criteria.
5. Document and communicate an agreed definition to sector.
6. Develop standard structured radiological reporting template for use with PPCT (Pancreatic Protocol CT).
7. Identify processes for the completion of the synoptic report at health service sites to enable documentation of a completed synoptic report in the medical record.
8. Identify processes for the annotation of the anatomical resectability status in the MDM meeting summary notes and ensure this is documented in the patient's medical record.
Pilot Study Phase 2
1. Pilot newly developed structured radiological reporting template (built using an agreed definition) in two metropolitan, key pancreatic health services.
2. Disseminate results and monitor uptake.
3. Report to the Project Steering Committee and Working Group.
4. Produce a summary report of the study.

Arriving at the agreement to use the International Guidelines

The 2017 Pancreatic Summit identified that there was a clear lack of a locally accepted common definition of borderline resectable disease for pancreatic cancer in Victoria, despite the existence of international guidelines that documented how to define resectability in pancreatic disease.

To ensure collective input to address this problem, the Project Team approached clinicians from the surgical, radiology and medical oncology disciplines to participate in key discussions, to gain input and perspectives.

A Working Group was established with representation from SMICS and NEMICS catchments as well as a third, metropolitan based Western and Central Melbourne Integrated Cancer Service (WCMICS), that similarly performs high volume pancreatic surgery. Two regional areas, Geelong and Ballarat were also invited to become members. Overall, the Working Group included 5 surgeons, 7 radiologists and 2 oncologists, who also represented the Upper Gastrointestinal Cancer Registry (UGICR) and Abdominal Radiology Group of Australia and New Zealand (ARGANZ).

It was noted that a number of guidelines already existed, for example the *International consensus on definition and criteria of borderline resectable pancreatic ductal carcinoma 2017* guidelines, the *AGITG Pancreatic Cancer Surgical Guidelines 2015*, and the *National Comprehensive Cancer Network (NCCN) Clinical Practice Guidelines in Oncology, Pancreatic Adenocarcinoma*, which determine operability, and are used by the radiologists as a guide for reporting.

Overall, the approaches varied and were not consistent. And although the topic of what constitutes borderline cases had been raised in the past, no Australian standard was widely adopted. During the course of meetings, it was also noted, that the group did not set out to replace any existing agreed guidelines but rather wanted to adopt a set of existent guidelines.

The Working Group agreed that the purpose of the project was to ensure consistent radiological reporting of the anatomy of pancreatic cancer. The group also noted the importance of using the same terminology to collect data.

Following group discussion, it was noted that the most appropriate guidelines for consideration were the ***'International consensus on definition and criteria of borderline resectable pancreatic ductal carcinoma 2017'*** guidelines. They were in existence, followed a robust process, and were recent. They also included the extensive views of groups around the world and incorporated the NCCN guidelines.

It was acknowledged however that the International Guidelines went beyond radiological parameters, and as this project would focus on the radiological definition only, **neither the biological nor the conditional** definition would be part of the scope of this project.

At a meeting on 7 May 2020, the group unanimously agreed to adopt the 'International consensus on definition and criteria of borderline resectable pancreatic ductal carcinoma 2017 guidelines to classify resectability in non-metastatic pancreatic ductal carcinoma (PDAC)', for use in Pancreatic Protocol CT (PPCT) reporting in Victorian health services, to ensure pancreatic cancer resectability status was appropriately and consistently classified to ensure appropriate patient management.

It was recognised that this project offered the unique possibility of introducing a statewide approach to classifying and documenting resectability from an agreed, common radiological criteria, that would facilitate a reduction in the variation in care, and this as a milestone could be seen as a world first in pancreatic cancer.

The development of the synoptic report, a co-design process among various disciplines

The benefit of a consistent way of describing a pancreatic CT scan is established in literature as a vital element of good patient care.

“...structured radiology reports offer unique opportunities to improve the quality of a radiology report. By using standardised terminology, structured reports enhance clarity and improve communication of radiological findings.” p72 It was also demonstrated that “...surgeons were more confident about tumour resectability using structured reports compared to nonstructured reports” p69

To improve patient care, it is imperative for the reports to be timely and accurate and to answer the clinical question. For a health-care system, these may be the most important, readily available metrics by which the value of radiology service could be measured. p66

Checklist style reports can reduce diagnostic errors... Positively impacts research in radiology by facilitating data mining. p68”

Source: Structured Reporting in Radiology, © 2018 The Association of University Radiologists.

The Project Working Group sought to use the agreed set of 'International consensus on definition and criteria of borderline resectable pancreatic ductal carcinoma 2017' and the National Comprehensive Cancer Network (NCCN) guidelines 2016 (Isaji et al, 2018; NHMRC et al, 2018), to build a radiological synoptic reporting template to be used by radiologists for the purpose of describing a pancreatic protocol CT scan for discussion at MDM.

The Group agreed that a REDCap research database developed by Vanderbilt University (Nashville, Tennessee, USA) for not-for-profit organisations and researchers to capture data would provide a readily available and accessible tool for the development of the report.

The raw report fields were developed by the radiologists participating in the group, in consultation with their surgeon and medical oncologist colleagues. The draft document was then tabled, reviewed by the group, field by field, and the document further refined. The prototype was then tested on several suspected pancreatic cancer patient CTs at both pilot sites to provide further granular detail. The final template was accepted by the Working Group and tabled with the Directors of Radiology at both pilot sites, ready for testing in a clinical pilot environment.

The radiological synoptic report template was made up of the following sections:

1. Basic Details
2. Mass Characteristics*- sourced from the NCCN guidelines
3. Arterial Evaluation
4. Venous Evaluation
5. Conclusion and Resectability status.

A snapshot of the report is given in the image below. For a copy of the full report please refer to Appendix B.

The image displays two screenshots of a REDCap form used for data collection in a radiological synoptic report. The left screenshot shows the 'Basic Details' section, which includes fields for 'Time synoptic report started', 'URN', 'Hospital', 'Surname', 'First Name', 'Date of Birth', 'Sex', 'Date of CT scan for assessment', 'Date of synoptic review', 'Imaging source', 'Biliary stent present on staging scan?', 'CT Chest scan available?', 'Unequivocal distant metastases present?', and 'Appropriate pancreatic cancer imaging protocol?'. Below this is the 'Mass Characteristics' section, which includes fields for 'Mass Visible?', 'Mass size (cm)', 'Mass Location', 'Mass enhancement pattern', 'Pancreatic duct cut-off present?', and 'Bile duct cut-off present?'. A blue box highlights the 'Basic details & image quality assessment' section. The right screenshot shows the 'Arterial Evaluation' section, which includes fields for 'Superior Mesenteric Artery (SMA)', 'Coeliac Axis', 'Common Hepatic Artery (CHA)', 'Anatomical arterial variant present?', and 'Any aortic tumour contact?'. Below this is the 'Venous Evaluation' section, which includes fields for 'Main Portal Vein (MPV)', 'Superior Mesenteric Vein (SMV)', and 'SMV tumour extension to first jejunal draining vein'. At the bottom is the 'Conclusion and Resectability Status' section, which includes a dropdown menu for 'ANATOMICAL RESECTABILITY STATUS'. A green box highlights the 'Resectability assessment' section.

The radiological synoptic report collected around 60 discrete fields of data that described in detail the pancreatic cancer mass characteristics, blood vessel involvement and determined the extent of any disease spread (metastases). Despite the number of fields, it took on average only 6 minutes to complete.

The International Guidelines 2017 classify anatomical resectability using the following terms. This classification was applied to the new synoptic report.

- Resectable (R)
- Borderline resectable – venous involvement (BR-PV)
- Borderline resectable – arterial involvement (BR-A)
- Unresectable – locally advanced (UR-LA)
- Unresectable – metastatic (UR-M)

After further testing of patient CTs, the pilot leads at both sites determined that more fields were required to support the assessment of image quality. Dedicated data fields were agreed, then added and collected to help determine if the actual scan met the required standard for “appropriate pancreatic staging imaging protocol”, and if the image was of an adequate quality to allow the radiologist to proceed with the assessment of resectability. This data would also allow the Project Team to assess the number of inadequate CT scans at the end of the pilot.

Please refer to the image below, showing fields that helped determine if an image was of appropriate quality and if the radiologist should continue with the assessment.

Appropriate pancreatic cancer imaging protocol? <small>* must provide value</small>	<input type="text" value="No"/> <small>Refers to pancreatic imaging only. At least biphasic (pancreatic phase and portal venous phase with slice thickness and reconstructions 3mm or less).</small>
Reason for inadequate imaging (tick all that apply):	<input type="checkbox"/> Non-biphasic (pancreatic phase and portal venous phase) study <input checked="" type="checkbox"/> Axial slices thickness > 3mm <input checked="" type="checkbox"/> Reconstructions (coronal or sagittal) thickness > 3mm <input checked="" type="checkbox"/> Axial/Coronal/Sagittal PV phase > 3mm <input checked="" type="checkbox"/> Other
Other reason for inadequate imaging (please specify):	<input type="text" value="arterial phase excludes inferior HOP"/>
Do you wish to proceed with the assessment of resectability?	<input type="text" value=""/> <small>For patients with UNEQUIVOCAL DISTANT METASTASES, select YES to enable manual entry of resectability status of "Unresectable (Metastatic)"</small>

It was noted from the very beginning of the project, that the choice of REDCap as a key data holding instrument, allowed the development of a background logic calculation that could be built into the report, using the data entered by the radiologist directly into the database, to provide an automated resectability status result.

Given the report was built using the assumptions contained in the International Guidelines 2017, and the guidelines contained some ‘grey areas’ open to interpretation, the automated calculation reached an overall 88% matching rate between the radiologist manual assessment and the logic. Radiologists had benefitted from comparing their manual assessment with the logic produced result and were generally satisfied with the added functionality of the report.

It must be noted that the logic component did not at any stage replace the manual assessment of a CT scan by the radiologist.

Below is an extract from the synoptic report template in REDCap, showing the anatomical resectability field completed by a radiologist during the assessment with the logic calculated field below, both based on the International Guidelines.

Conclusion and Resectability Status

ANATOMICAL RESECTABILITY STATUS

*** MUST BE COMPLETED** This radiological anatomical resectability status must be entered and it **WILL** be included in the medical record

* must provide value

THE RESECTABILITY LOGIC CALCULATION IS FOR REFERENCE ONLY

This calculation has not been fully "tested" and **WILL NOT** appear on the medical record or be displayed in the downloaded pdf report.

Anatomical Resectability Calculation

1= Resectable (R) View equation

2= Borderline Resectable - Venous involvement (BR-PV)

3= Borderline Resectable - Arterial involvement (BR-A)

4= Unresectable - Locally Advanced (UR-LA)

5= Unresectable- Metastatic (UR-M)

To update calculation: Select "Save & Stay" option at the bottom of form to trigger update of calculation if you have altered your original responses to questions and the calculation hasn't updated.

The Project Team also added the "International consensus of classification of BR PDAC based on anatomical definition using CT imaging including coronal and sagittal sections" table of definitions to the end of the synoptic radiological report template located in REDCap. This provided a quick reference for radiologists less familiar with the status classification.

Please refer to the image below

International consensus of classification of BR PDAC based on anatomical definition using CT imaging including coronal and sagittal sections. (Table 2. Page 5)

Resectable: R	SMV/PV: no tumor contact or unilateral narrowing SMA, CA, CHA: no tumor contact
Borderline resectable: BR	Sub classified according to SMV/PV involvement alone or arterial invasion.
BR-PV (SMV/PV involvement alone)	SMV/PV: tumor contact 180° or greater or bilateral narrowing/occlusion, not exceeding the inferior border of the duodenum. SMA, CA, CHA: no tumor contact/invasion
BR-A (arterial involvement)	SMA, CA: tumor contact of less than 180° without showing deformity/stenosis. CHA: tumor contact without showing tumor contact of the PHA and/or CA. (The involvement of the aorta is categorized as unresectable. Presence of variant arterial anatomy is not taken into consideration)
Unresectable: UR	Sub classified according to the status of distant metastasis
Locally advanced: LA	SMV/PV: bilateral narrowing/occlusion, exceeding the inferior border of the duodenum. SMA, CA: tumor contact/invasion of 180 or more degree # . CHA: tumor contact/invasion showing tumor contact/invasion of the PHA and/or CA. AO: tumor contact or invasion
Metastatic: M	Distant metastasis \$.

SMV: superior mesenteric vein, **PV:** portal vein, **SMA:** superior mesenteric artery, **CA:** celiac artery, **CHA:** common hepatic artery, **PHA:** proper hepatic artery, **#:** In the cases with CA invasion of 180° or more without involvement of the aorta and with intact and uninvolved gastroduodenal artery thereby permitting a distal pancreatectomy with enbloc celiac axis resection (DP-CAR) [21], some members prefer this criteria to be in the BR-A category. **\$:** including macroscopic para aortic and extra abdominal lymph node metastasis.

Upon completion of the build of the master radiological synoptic report in REDCap, the Project Team focussed its attention on developing a solution that would enable data collection for CT scans that:

- originated from outside a hospital (external), versus
- those that originated from within the hospital (internal).

Two sources of CT scans, two synoptic report templates and the issue of re-reporting

In fact, the existence of two sources of CT scans, that would be tabled and discussed at the pilot site MDMs created a unique challenge for the project from the start.

Although the discussion and radiological interpretation of outside scans for the purposes of MDM is a standard practice, the Project Team had to ensure that scans originating from internal and external sources were equally documented in MDM notes, and a copy of the completed synoptic report was saved to the local medical record in both instances.

Internal CT scans

CTs for MDM meeting review that originated from an internal imaging source would be usually reported in a local Radiology Information System (RIS), part of the Picture Archiving and Communication System (PACS) imaging depository, located in a hospital radiology department. As any internal image is automatically directly reported in RIS, the synoptic report could be presented by the radiologist at MDM and automatically saved to the electronic medical record.

The new radiological synoptic report master developed in REDCap was thus converted into a word format to enable it to be uploaded onto RIS for PPCT reporting.

The fields were kept the same, however the structured formatting offered by the REDCap template was largely lost. The RIS platform also did not allow for the insertion of a background logic mechanism, thus any internally generated scans assessed in RIS would be completed manually only.

Although all hospitals have access to a RIS system of some sort, these differ in versions and feature capability, thus it could not be assumed that both pilot sites could easily translate the master template created in REDCap into their local RIS. This presented the first challenge.

External CT scans

The second, more complex challenge lay in the fact that many scans were routinely taken outside the hospital.

As generic CT reports are variable and the MDM process enables a re-review of these pancreatic protocol images by HPB specialist radiologists, the review of these externally produced scans is commonplace, however up until the point of the pilot, this review was not based on any agreed standardised criteria, and radiologists did not use synoptic or structured reporting to describe the anatomy of the disease. The reports were verbal.

“Studies show that the use of nonstructured reports using narrative language may serve as an obstacle to optimal patient care. Excessive variability in language, length, and style can minimize report clarity, making it difficult for referring physicians to identify key information needed for patient care. p66”

Source: Structured Reporting in Radiology, © 2018 The Association of University Radiologists.

As there was no formal written report produced to describe the externally generated CT image, there was no need to save it anywhere.

Upon closer examination of externally generated scans being described using the new synoptic template, a level of sensitivity also arose around the medico-legal implications of ‘re-reporting’ of these scans.

However, upon consultation with the Royal Australian & New Zealand College of Radiology (RANZCR), and a participating health service, it was agreed that the practice of re-review was not considered new, rather the new radiological synoptic report would allow a more systemic way of describing, and documenting the radiological detail by a specialist radiologist, in this way assisting with treatment decisions at multidisciplinary team meetings (MDMs).

As externally generated scans had to be reported in REDCap, the Project Team needed to find a host location for the REDCap database that was both secure and would meet the requirements of the ethics approval process, as patient data was being collected outside the hospital medical record system, as REDCap is a web-based tool.

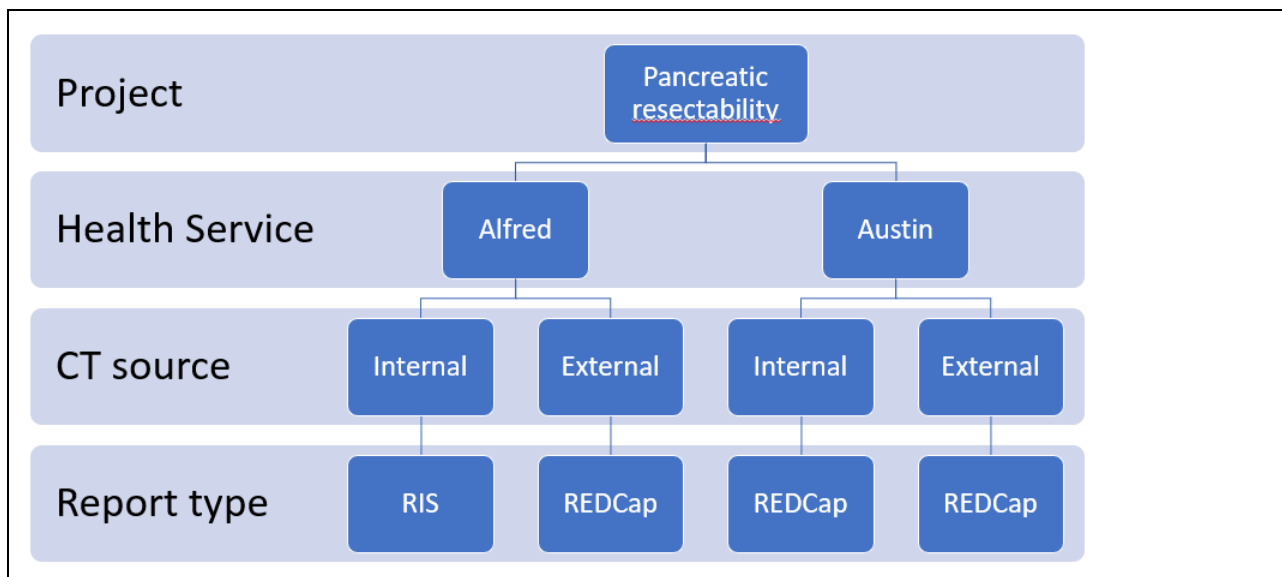
Most health services host their own REDCap databases for research purposes; however, this option was soon dismissed as variations between hospital versions exist, and using this approach, the data would be collected locally only. An ethics approval process would also have to be explored.

The Project Team and the wider group also approached the existing state-wide Upper GI Cancer Registry (UGICR), hosted by Monash University.

The UGICR had experience in creating data collection instruments using REDCap, and Monash University, which hosted the registry had the required infrastructure to ensure secure storage of data. It also had the ethics and governance framework with key pancreatic health centres across the state that would support the build for the purposes of the project.

Importantly, the project itself also aligned closely with registry's aims of improving quality of care.

In summary, the following data collection process was agreed:



REDCap data capture, the UGI Cancer Registry and ethics

The Working Group clearly identified REDCap as their preferred mechanism for building and hosting the new radiological synoptic report.

REDCap was a secure web database application that did not require health services to install new software.

The REDCap solution also provided easy access for clinicians. Radiologists would be provided with a unique login and password to access and enter information into the pilot REDCap database, and surgeons involved would similarly be granted access, to enable them to read the completed reports in read-only mode, if needed.

A partnership with the UGI Cancer Registry

The Upper Gastrointestinal Cancer Registry (UGICR), a clinical quality registry, established in 2016 was developed to monitor and report on quality-of-care information on patients diagnosed with oesophagus, stomach, liver, biliary system and pancreas cancer.

It also already collected data with the assistance of its auditor team on pancreatic cancer resectability documentation in the patient’s medical record at diagnosis, at pancreatic surgical sites nationally. This included the two pilot sites, Alfred Health and Austin Health.

Most importantly, the registry also collected data in REDCap.

The Project Team along with the participating clinicians, recognised that the collection of pilot data in REDCap and its subsequent storage in the registry, would allow **a central collection point**, ensuring standardisation of data collected, and at the same time add value to the registry by providing reliable pancreatic cancer resectability data for future research and analysis, which is often reliant on the use of retrospective data. Additionally, rather than simply building a tool to correctly classify pancreatic cancer resectability, developing a platform to collect and analyse data derived from the tool would allow an understanding of the distribution of pancreatic cancer resectability stages across participating sites representing an invaluable tool to monitor variation in care in real time.

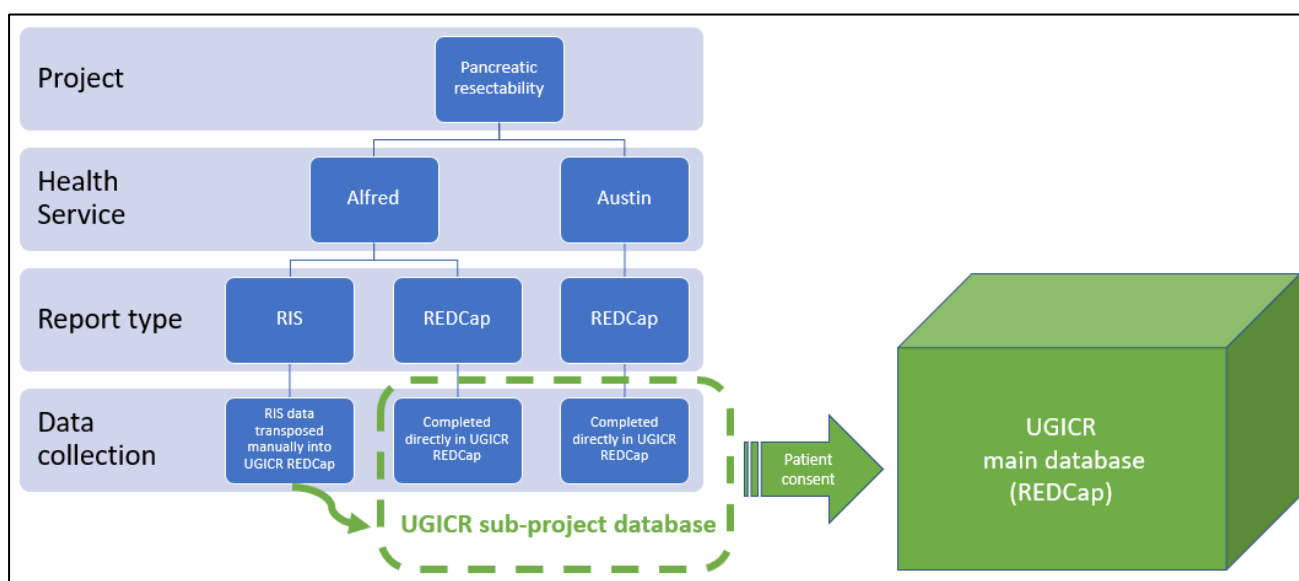
It was agreed at the start of the pilot, that the CT imaging data from the radiological synoptic reports would be collected and stored separately from the main registry, in a dedicated REDCap sub-project database. A process would also be put in place to ensure that existing patient UGICR invitation processes would need to be completed before **any** patient data would be sent and combined with the main registry data at any stage.

Finally, it was decided, that as the UGICR auditors already collected resectability data from the medical record, for the few synoptic reports that would be entered into RIS for the internal CT scans taken at Alfred Health, these would also be re-entered into REDCap at a later date. This would ensure a central data depository was maintained for all synoptic reports as part of the study. It is important to note that

this small group of reports was cross checked, as part of the data collection process to ensure accuracy of data translation between systems.

The Project Team in partnership with the UGICR submitted a detailed ethics submission allowing full site approval for the two pilot sites.

The diagram below illustrates data flows at both sites.



Using the synoptic report at MDM, and documenting the resectability status in the patient’s medical record

Once the Project Team developed the template report and established the two housing options for the tool: namely the local RIS system, and the UGICR registry’s REDCap, its next challenge was to ensure that the resectability status arrived at in the radiological synoptic report was recorded in the MDM summary note, and then saved to the patient’s medical record at both health services.

It was known that (MDMs) are considered best-practice for discussing the results of diagnostic tests and planning the subsequent treatment and management of patients with pancreatic cancer.

It was also routine for patients with suspected pancreatic cancer to have an abdominal CT scan as part of their diagnostic imaging investigations. These would have been reviewed by a radiologist prior to presentation at an MDM.

But the review of CT scans, up until the study commenced did not follow agreed standardised criteria, and radiologists did not use synoptic or structured reporting to describe the anatomy of the disease. This meant that the classification of resectability was variable and not well documented.

If a patient’s CT scan was completed internally (same health service as the MDM) a radiologist reviewed the images and produced a written radiological report before presenting the findings at the MDM. This was completed directly in the RIS.

However, if the patient’s CT scan was performed externally, a commonly found occurrence, then the MDM radiologist reviewed the images prior to the MDM but provided a verbal report of their findings, which may have been noted in the MDM record but was often inconsistent across MDM meetings at different sites, with the task of documentation generally falling to a junior registrar scribe.

Furthermore, the two pilot sites had their own unique MDM documentation systems and processes. Registrars, responsible for recording MDM outcomes, also had regular rotation rounds.

It is important to note that the radiological data collected in the synoptic report only contributes to determining the **anatomical resectability status**.

It is this status that was recorded as part of the pilot study.

It must be noted that the biological and conditional clinical information also needs to be determined to arrive at the **overall resectability status** of a patient, enabling the multidisciplinary team (MDT) to develop a treatment plan.

To ensure consistent documentation of the anatomical radiological resectability status at pilot sites, registrars assigned as scribes in both MDMs were given specific instructions on how to document this in the MDM summary.

At **Alfred Health**: HPB MDM outcomes were documented in free text using a standard phrase, in a basic Microsoft Access database. The registrar was instructed to use the following statement to document the status. 'This patient's scan was assessed using the radiological synoptic report, and using that definition is classified as <insert status>'. [Please refer to the image below.](#)

RADIOLOGY:
CTAP March 2020: Initial bulky tumour, locally advanced with invasion of coeliac axis, common hepatic artery and superior mesenteric artery.
CTAP 09/11/20: Decreased in size (now to 3.6cm) but vascular involvement remains with involvement of coeliac axis, replaced right hepatic, common hepatic artery (narrowed), and probably abutment of SMA. Portal vein is encased without being narrowed.

IMPRESSION
Despite reduction in size, remains a large tumour. IRE unlikely to be of utility.

Synoptic report: This patient's scan was assessed using the radiological synoptic report, and using that definition is classified as unresectable (locally advanced).

PLAN
Ongoing chemotherapy

At **Austin Health**: HPB MDM utilised a dedicated MDM software platform (CANMAP), where a labelled dropdown field to record findings was added to document a management plan.

The dropdown contained the five resectability status options as per the adopted International Guidelines 2017, plus an option to note the actual image quality. If an image did not allow accurate assessment, it was recorded as 'Inadequate imaging – unable to classify'. [Please refer to the image below.](#)

The screenshot shows a software interface with several sections. On the left, there are sections for 'Supportive Care Issues', 'ECOG Performance Status', 'Pancreatic anatomical radiological resectability status', 'Summary of MDM discussion', 'Recommended management plan elements', and 'Recommended management plan'. The 'Pancreatic anatomical radiological resectability status' dropdown menu is open, showing the following options: Resectable (R), Borderline Resectable (BR-PV), Borderline Resectable (BR-A), Unresectable (Locally Advanced - LA), Unresectable (Metastatic - M), and Inadequate imaging - unable to classify. Below this, there are checkboxes for various management plan elements: Surgery, Radiotherapy, Other, Interventional Endoscopy, Regional Therapy - SIRTEX, Local Therapy - RFA, Local Therapy - Microwave, PEI Percutaneous ethanol injection, Observation, Chemotherapy, Palliative Care, Interventional Radiology, Regional Therapy - TACE, Regional Therapy - DC BEADS, Local Therapy - Laser, and Referral for liver transplant.

As a copy of the MDM discussion outcome is already routinely uploaded to the medical record at each site, this mechanism was utilised to ensure the radiological resectability status would be included in the patient's medical record.

Saving a copy of the completed synoptic report to the patient medical record

The radiological synoptic report, when generated for internal scans, was reported in RIS, and was automatically linked to the patient medical record.

But most of the pilot synoptic reports were completed in REDCap, which was not automatically linked to the health service medical record.

The transfer of the completed synoptic report from a separate REDCap platform, in this instance hosted by the UGICR, required significant exploration at both health services, and although a relatively simple IT solution acting as a 'bridge' between the REDCap environment and health service medical record was possible to develop, this was outside the scope of the project due to budgetary constraints. We therefore concentrated on manual transfer options.

The synoptic report, once completed by a radiologist allowed them to save it in a PDF format in the REDCap environment. The document was then saved to the radiologist's desktop and uploaded to the medical record by emailing it directly to the hospital Health Information Systems (HIS) Team in the case of the Austin site. A simple one step process, however still requiring the radiologist to take on an administrative task. It also required the HIS team to save the document directly to the patient's medical record.

In the case of Alfred Hospital, the document was similarly saved to the radiologist's desktop, however here the radiologist had to complete several administrative steps, that would enable them to save the document to an agreed folder, directly in the medical record. This was far more cumbersome as an administrative process but proved the only manual way of saving the PDF of the synoptic report. Having consulted the radiologists at the site, we agreed to go ahead and apply this method. It is important to note that this practice is unsustainable in the long term and will need to be refined and automated in future iterations of the roll out to ensure consistent and independent upload of the radiology report.

As part of imbedding the practice, both pilot site radiology teams were also provided with individual training sessions and detailed manuals for completion of the synoptic reports, together with the process for report download and transfer to the medical record.

It is crucial to note that only patients registered with the health service, who had their Unit record (UR) numbers allocated at the time of MDM had their synoptic reports, and their MDM summaries saved to their local medical record.

This is because patients had to be registered to have a medical record created at the health service. Some patients listed for discussion at MDM were **not** registered prior to their case being presented. This meant that neither their MDM outcome summary nor a copy of their radiology synoptic report was able to be saved to the patient medical record. (as no patient medical record existed for that patient).

A distinction also had to be made between partially completed and fully completed radiological synoptic reports.

The variable quality of externally acquired images had necessitated the refining of the synoptic template to capture the limiting factors associated with sub-standard pancreatic protocol imaging. *(Please refer to the CT scan quality assessment image on p15)*

A partial report was completed when poor-quality imaging was presented for radiological synoptic assessment of suspected pancreatic cancer, in these cases resectability status was not determined.

A full synoptic report was completed when the CT imaging presented for review was of an appropriate quality (ideally a pancreatic protocol CT – PPCT) to clearly determine the tumour mass characteristics, the extent of arterial and venous involvement, and the absence or presence of aberrant vessels.

Pilot Data Collection

Data for this study was collected electronically directly through the REDCap synoptic report template located at the UGICR, for external scans at both sites, as well as for internal scans at the Austin Health site.

Data for internal scans at the Alfred was collected directly through RIS.

As REDCap is a database, field data was easily downloadable into an Excel spreadsheet.

A separate Administrative Database tool was also created in the REDCap database to allow the Project Team to track and check the progress of entries of resectability status in MDM summaries at pilot sites, and that those summaries were subsequently saved in the medical record.

Similarly, the download of completed synoptic reports and subsequent saving of these to the patient's medical record was checked and tracked using this mechanism

For CT reports entered directly into the hospital RIS at Alfred Health, a project team member reviewed the completed report located in the medical record and then proceeded to manually enter a copy of the data into REDCap. This RIS data entry would be double checked by another team member.

The manual data entry of synoptic reports from RIS into REDCap represented 16% of total reports. However, this process allowed us to keep all pilot data in one single central location.

Program of work

Measurables

To monitor the uptake and measure the relative success of implementing a radiological synoptic reporting tool in a clinical setting, four discrete project measures were determined.

1. A radiological resectability synoptic report was completed.
2. The resectability status was able to be determined.
3. The resectability status was documented in the MDM outcome summary and uploaded to the patient's electronic medical record (EMR).
4. The radiological resectability synoptic report was uploaded to EMR.

Project measure 1 describes a report that was completed. The radiological synoptic report is counted as completed either as a full synoptic report or a partial report.

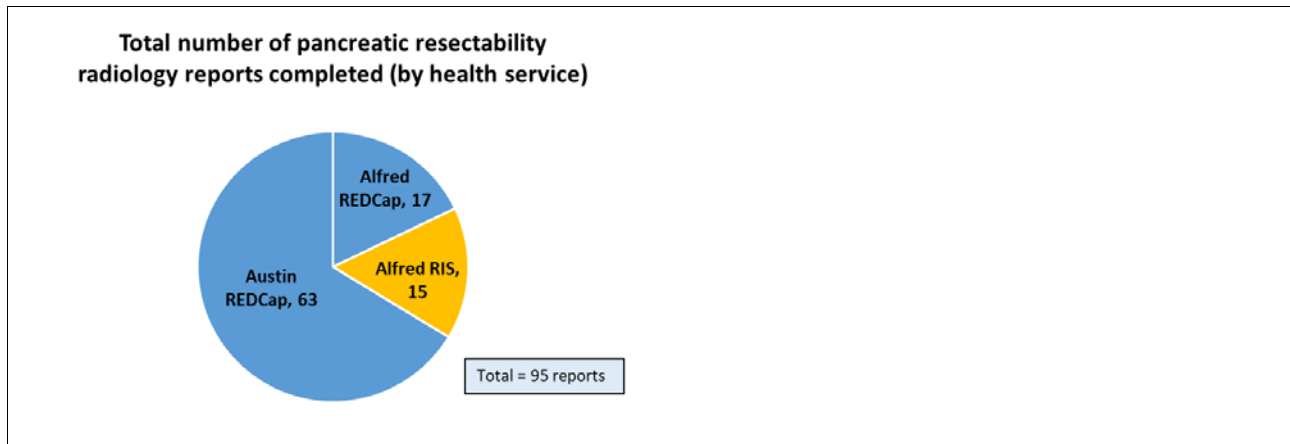
Project measure 2 describes whether the radiologist was able to arrive at an anatomical resectability status based on the CT images presented for review. Noting that if the abdominal CT imaging is of poor quality, it is not always possible to clearly define the extent of the tumour involvement and/or the overall spread of disease.

Project measures 3 and 4 could only be determined for patients who were registered at the health service conducting the MDM. The importance of having the resectability status and a copy of the synoptic report available on the patient medical record for the wider treatment team to access is also highlighted in these measures.

Pilot Results

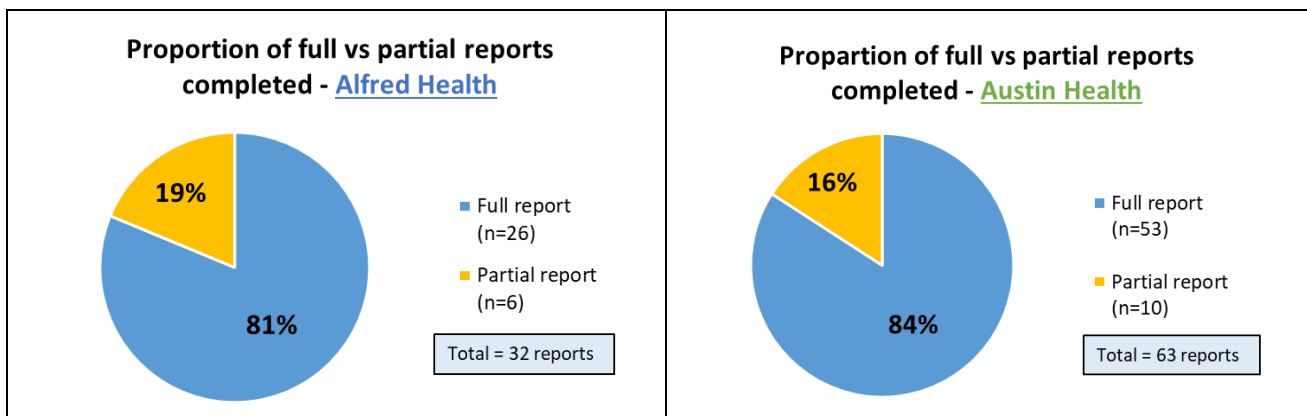
Project measure 1 | Radiology report completed

A total of 95 radiological synoptic reports were completed by radiologists at the two pilot sites during the 12-month pilot. The following diagram illustrates how the reports were collected by each health service.



Overall, 83% of synoptic reports completed as part of the pilot, were fully completed reports.


It is worth noting that the number of partial reports completed at both hospitals represents a similar percentage at both sites. Please refer to the charts below.



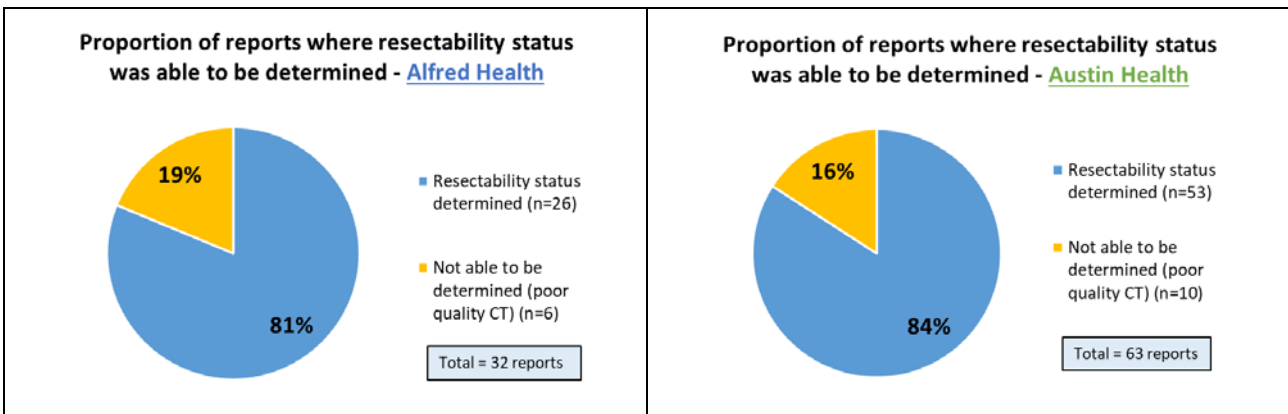
Project measure 2 | Resectability status determined

As mentioned earlier in this report, a resectability status for a patient can only be determined from appropriate quality imaging.

Overall, (83%) of CTs presented for MDM review as part of the pilot study, were fully completed reports of an appropriate quality to support resectability assessment.



By comparison at the hospital level, at the Alfred, (81%) of reports were fully completed and had their resectability status determined, this figure rose slightly to (83%) at the Austin. Please refer to the charts below.



Project measure 3 | Resectability status documented in the MDM summary and uploaded to the electronic medical record (EMR)

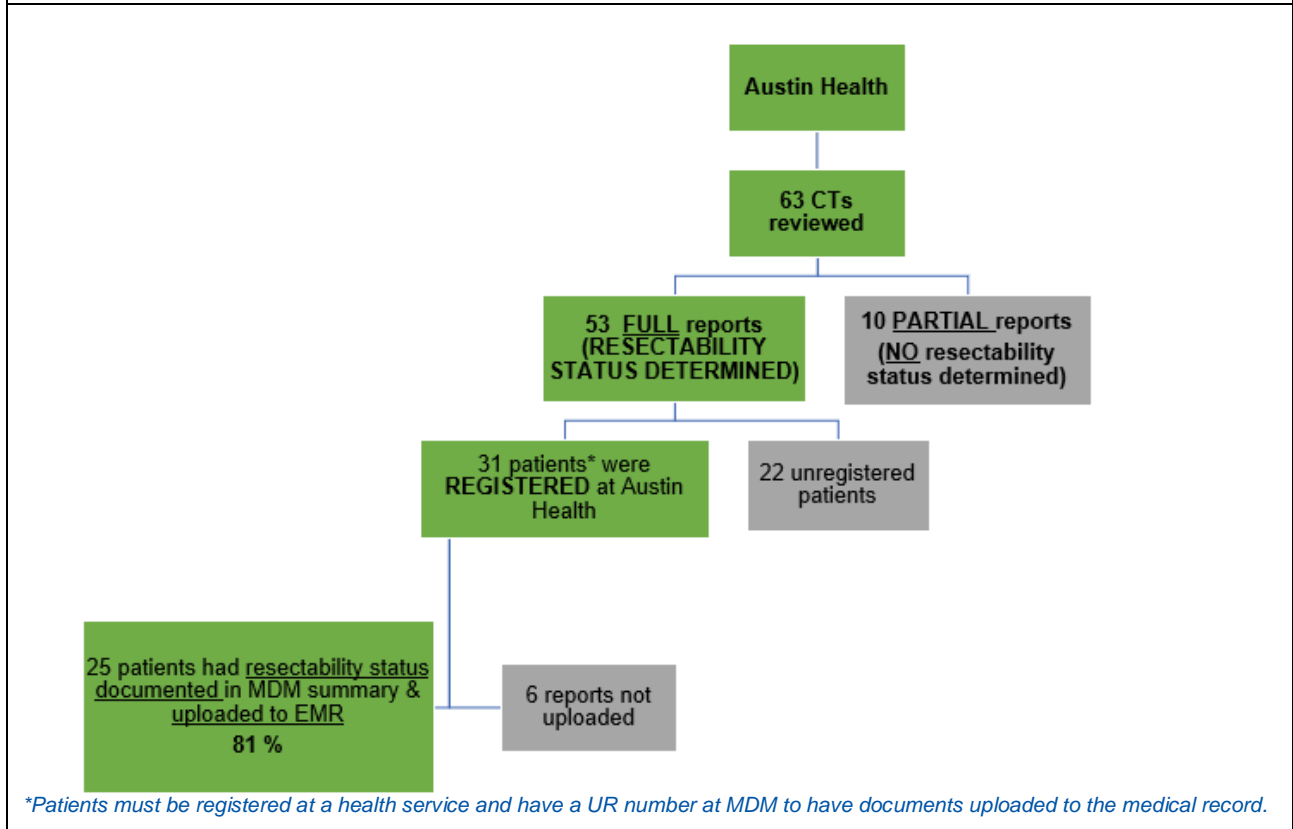
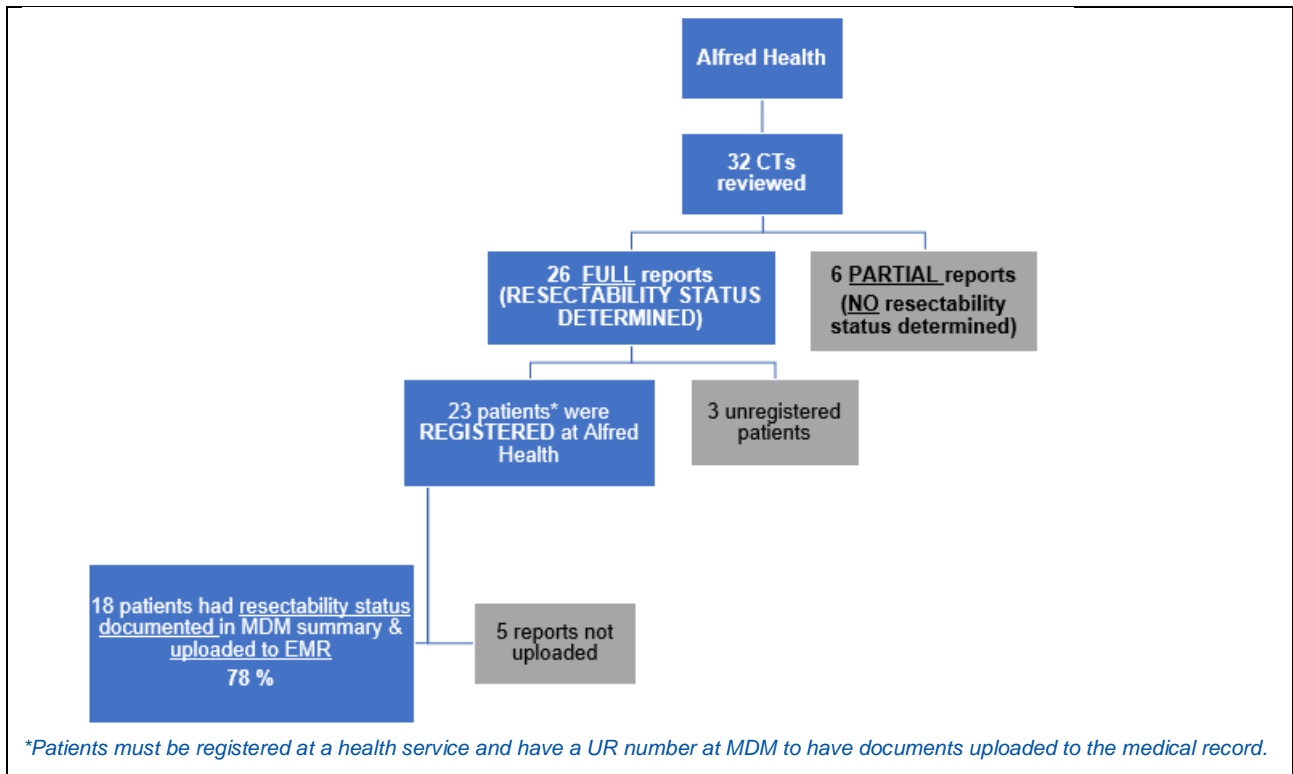
This measure tracks the documentation of the anatomical resectability status presented by the radiologist during the MDM discussion, in the patient’s medical record.

Overall, (80%) of patients eligible for inclusion in this measure (*i.e., registered and having a UR number) had a record of their resectability status documented in their MDM summary and uploaded to the medical record.

The proportion of patients with a resectability record that were uploaded to their electronic medical record was similar between the two pilot sites.

Austin Health performed slightly better on this indicator, achieving **(81%)** compared to the Alfred’s rate of **(78%)**, possibly demonstrating the ease of recording the status using a drop-down and the availability of dedicated administrative staff to upload the MDM summary to the EMR.

Project measure 3 flowcharts - defining the cohort and the resultant measure (by health service)



Project measure 4 | Radiology report uploaded to the electronic medical record (EMR)

This final measure tracks the upload of the actual synoptic radiology report (both fully and partially completed) to the patient’s medical record.

Again, patients eligible for inclusion in this measure were those *registered at the health service.

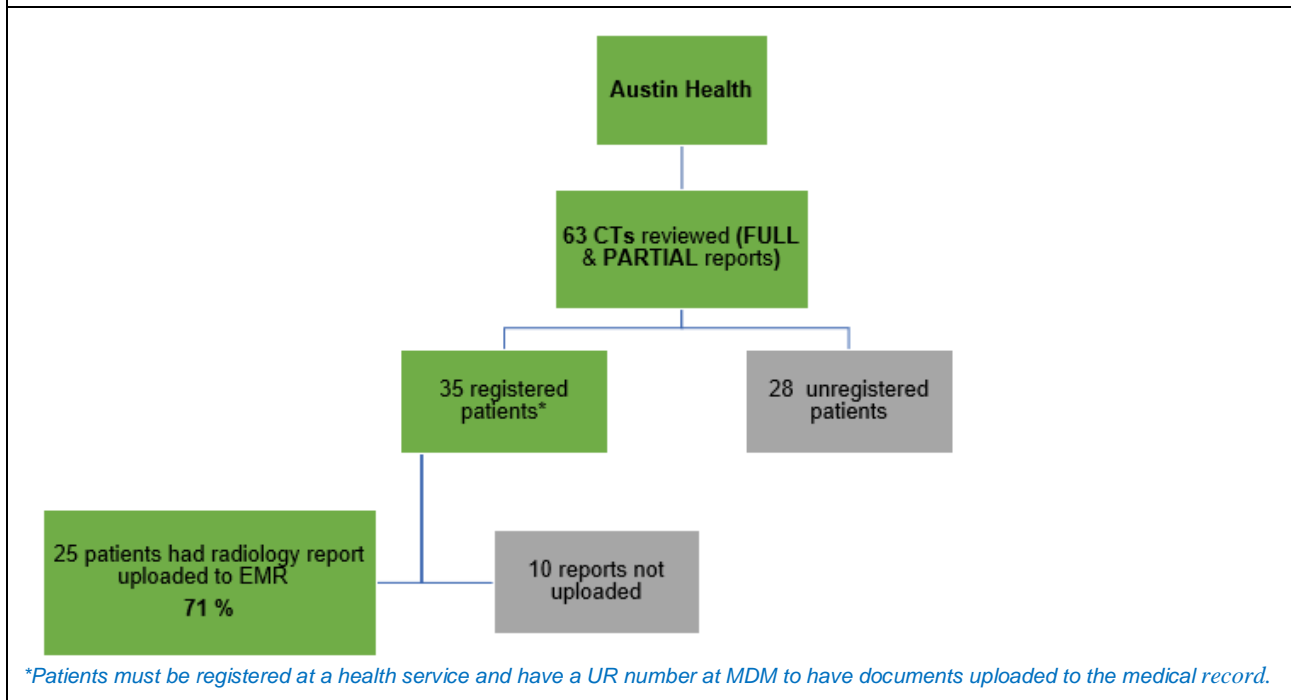
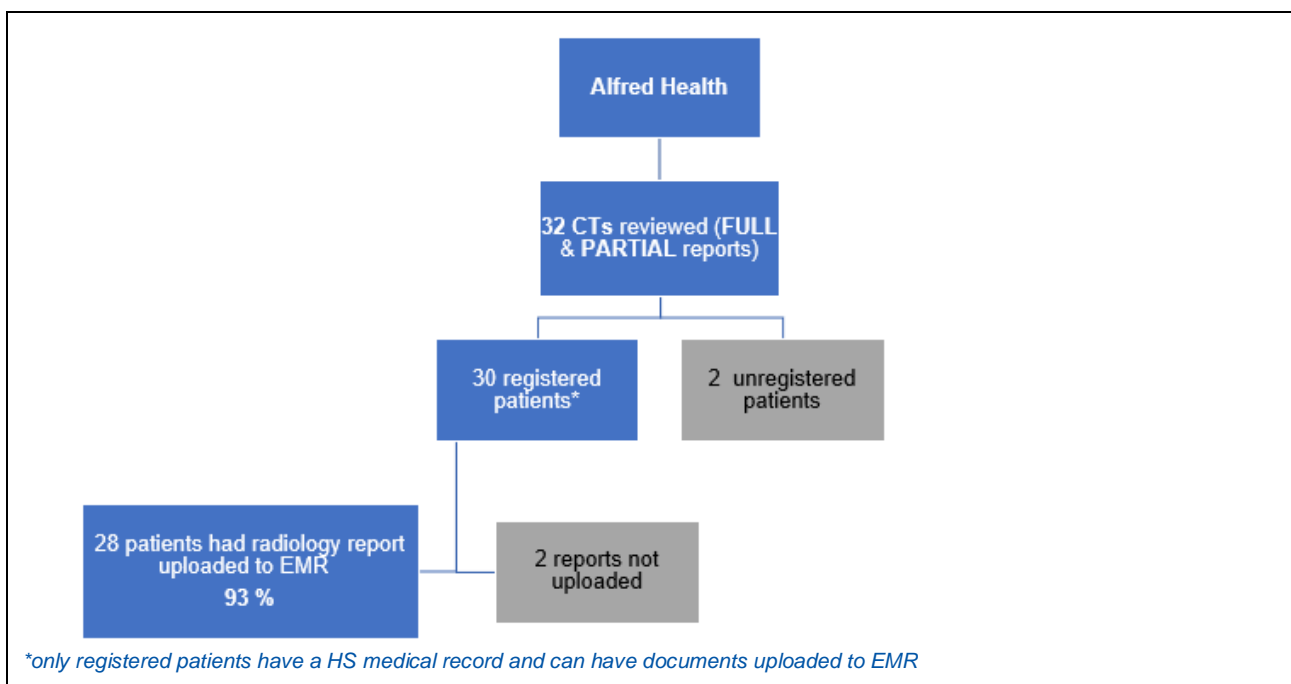
Overall, (82%) of registered patients in the pilot project had a copy of their radiology synoptic report uploaded and available for view on the hospital EMR.

The Alfred Hospital recorded a higher proportion (93%) of radiology reports uploaded to the EMR.

Just under half of the radiology reports documented at the site were completed on RIS and this likely explains the better performance due to the reduced administrative burden of transmitting these reports to EMR.

In comparison, the Austin Hospital managed (71%) of radiology reports uploaded to the EMR.

Project measure 4 flowcharts - defining the cohort and the resultant measure (by health service)



Key lessons learned

Enablers

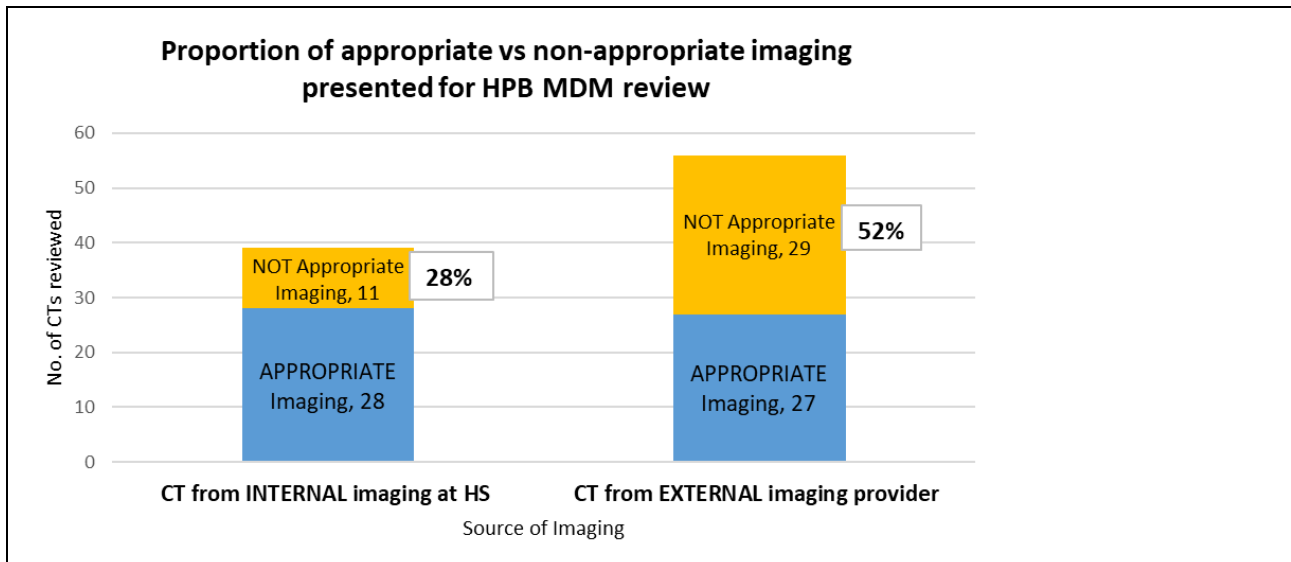
1. The commitment of the radiologists and surgeons who contributed their time and knowledge to the overall project, championing the new radiological reporting tool with their teams at the two pilot sites, and at their respective HPB MDM meetings.
2. The engagement of the Directors of Radiology Departments at the two pilot sites, and key MDM clinicians ensured ongoing clinical support for the project.
3. The in-kind support of the UGICR in completing the ethics requirements and creating the clinical synoptic reporting tool in REDCap that was used in the pilot project.
4. The pre-existing UGICR ethics approval to collect pancreatic cancer data across pancreatic surgery sites across Victoria.
5. Choosing REDCap as a platform to build the synoptic report and its subsequent compatibility as the data entry mechanism for pancreatic data collection in the UGI registry.
6. A Project Team combining two strong and distinct skills sets: clinical and health service technical knowledge, and project management and leadership to successfully steer the project to completion.

Challenges

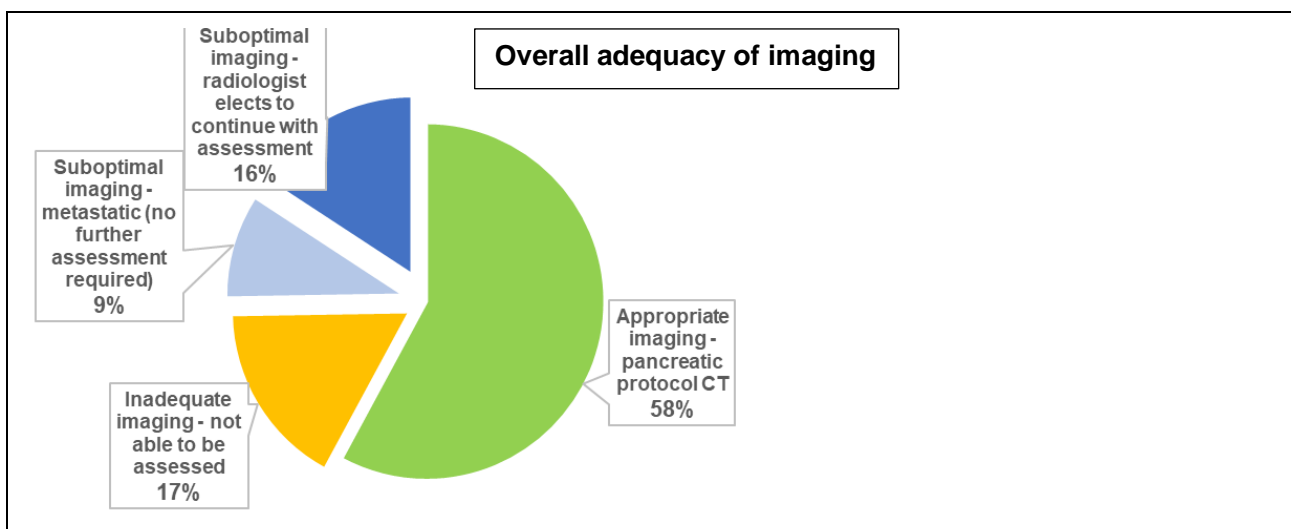
1. Identifying a suitable reporting and documenting process to be used for both internally and externally acquired CT scans given there was no pre-existing mechanism to document the findings for external scans.
2. Implementing a workflow that crosses both internal and external hospital reporting environments and acknowledges existing sensitivities and previously unspecified re-reporting concerns.
3. Transferring the clear visual design of the REDCap synoptic reporting template into RIS hospital software.
4. Implementing a workflow in existing MDMs that have had minimal or no investment in administrative assistance and meeting management infrastructure.
5. Understanding the complexities of hospital IT (Information Technology) systems, firewalls, and the compatibility of REDCap in these secure environments.
6. Regular periodic rotations of junior medical registrars, and the issues this presents with limited opportunity for a comprehensive handover of unit specific information. The MDM workflow for the pilot needed to be one step ahead of the incoming junior medical registrar whose role is to scribe and manage the EMR documentation process of MDM outcomes.

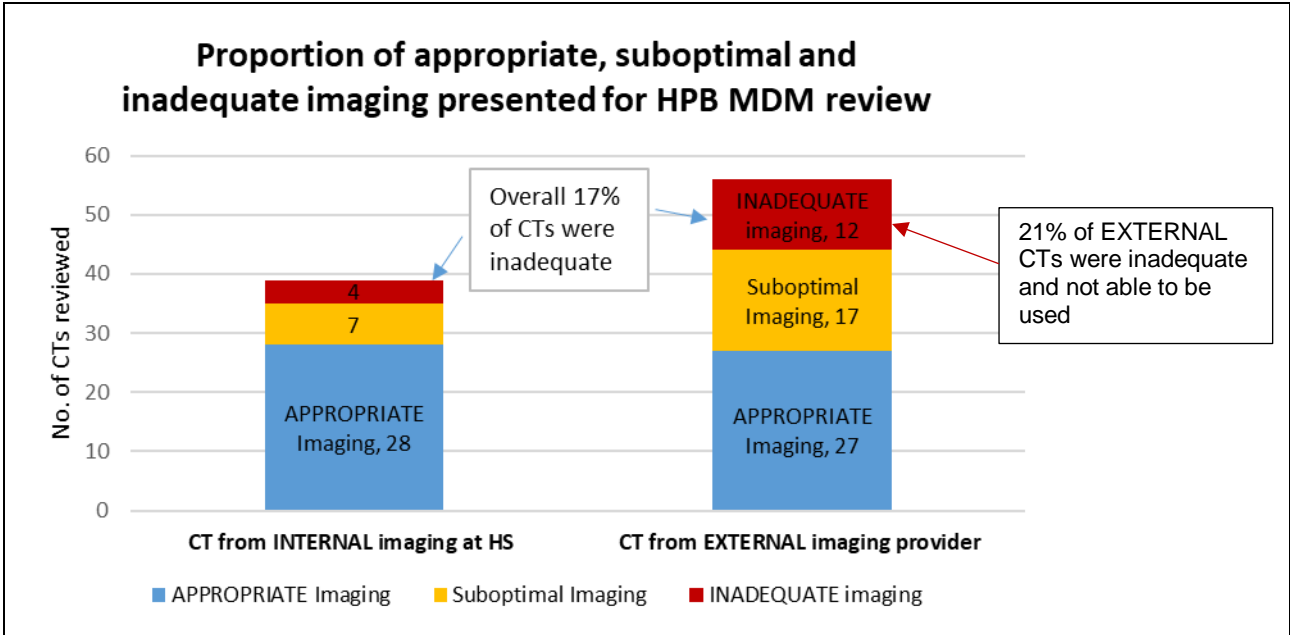
Lessons learned

1. Separate reporting and documenting solutions are required to cover both internally and externally acquired CTs. A substantial proportion of the CTs presented during the pilot study came from external sources, which did not have an established reporting mechanism as they were traditionally discussed verbally with minimal written documentation.
2. The quality of CT imaging presented for MDM review varied. Poor quality imaging affects the ability to clearly define disease and hinders the assessment of pancreatic resectability.



3. 59% of CT scans presented for MDM review were from external radiology providers and presented issues regarding re review and documentation of findings for MDM radiologists.
4. Determining the quality of the imaging is an important first step in the radiologist's resectability assessment process.
5. 17% of the imaging presented for review was of inadequate quality for the radiologist to perform any resectability assessment. In 25% of cases, the radiologist was able to continue with a substandard CT image and provide an assessment, 16% of these were of poor quality and 9% were clearly metastatic, so no further assessment was required. [See graph below](#)





6. The synoptic report could be seen as a useful handover document for patients to take when seeking a second surgical opinion.
7. There is a need for an appropriate timeframe to allow radiologists to review their scans prior to MDM. This means the preparation of agendas for meetings must follow a process that allows timely review of CTs in time for the MDM meeting, with at least 24 hours between publication of a final agenda and the actual meeting. Variation in MDM HS processes are highlighted below.

Report completed:	Alfred Health	Austin Health	Overall
<u>Before</u> MDM	26 (81%)	37 (59%)	63 (66%)
After MDM	6 (19%)	26 (41%)	32 (34%)
Total:	32	63	95

8. The synoptic reporting process supported radiologists, in that it provided a structured and robust way of assessing resectability for pancreatic cancer.

For a full list of lessons learned please refer also to Appendix E. Other Project learnings

Outputs and Outcomes

Project Outputs

1. Agreement of common definition for resectability and adoption of the universally accepted “International consensus on definition and criteria of borderline resectable pancreatic ductal adenocarcinoma 2017.”
2. Development of a new synoptic radiological reporting tool that can be applied to CT scans presented for MDM review that are sourced both internally and externally.
3. Completion of a pilot testing the tool above at two HPB MDMs in two health services.
4. The radiological reporting template was tested and applied to 95 patients, completing a pilot phase for the tool, enabling possibility of further adoption in key pancreatic centres in Victoria.

Current Outcomes

1. Radiologists adopted the use of a new standardised radiological synoptic report in two health services to assess CT scans for MDM review.
2. Patients at Alfred Health and Austin Health have their pancreatic cancer resectability defined using a common definition of resectability, reducing variation in treatment planning and care.

Possible Future Outcomes

1. Patients are appropriately and consistently managed across the state, reducing variation across public health services if widely implemented.
2. Improve pancreas cancer patient outcomes within the SMICS and NEMICS region.
3. Result in fewer unnecessary surgeries being performed with agreed, evidence-based criteria to guide assessment of surgical potential.
4. Provide a further level of detail to be added to the data captured by the Upper Gastrointestinal Cancer Registry (UGICR), with more accurate and granular reporting of disease staging and resectability status in patients with non-metastatic PDAC.
5. Enable comparative analysis of studies involving surgery and systemic therapies for pancreatic ductal adenocarcinoma (PDAC) and assist in the interpretation of future clinical trials.
6. Improve surgical confidence in resectability information provided at MDM, allowing guided clinical decision making in the management of patients with non-metastatic PDAC.
7. Result in Victorian health services having a single standard statewide definition for resectability in pancreatic cancer management, ultimately improving outcomes for all pancreatic cancer patients seeking care in the state of Victoria.
8. Support clinicians in identifying unresectable disease in patients with advanced cancer and help to facilitate timely referral to palliative care.
9. Broaden scope of treatment options for patients through improved assessment of disease staging.

Future Sustainability

The Victorian Integrated Cancer Services will be working with individual health services to agree processes to ensure sustainable use of the new synoptic report. The project will be tabled at the upcoming repeat Pancreatic Cancer Summit to be held in March 2022.

Recommendations

1. The new pancreatic cancer radiological synoptic report offers a quick, consistent, and accurate way of classifying and documenting anatomical resectability in pancreatic patients. Post pilot clinician feedback confirms it is a valuable and useful tool for radiological assessment and surgical decision-making. It is recommended this report be implemented in all Victorian HPB MDMs that perform treatment planning for pancreatic cancer patients.
2. As synoptic reporting of pancreas CTs is a specialised skill, it should be carried out by experienced radiologists who review a high volume of pancreatic cancer imaging. It is recommended that the synoptic reporting tool be made available specifically to HPB MDMs responsible for treatment planning of pancreatic cancer patients.
3. Data from the new radiological synoptic report should be centrally collected and housed in REDCap (Research Electronic Data Capture) using the existing UGICR (UGI Cancer Registry) database to support statewide outcome monitoring to reduce variation in care, until such a time as the Victorian Cancer Registry (VCR) can perform this function.
4. Reporting of **internally** generated CTs should be completed on a RIS template, where available, to ensure the report is directly uploaded to the health service EMR.
5. Reviews of **externally** generated CTs for MDM will require a separate housing platform as these reports are currently not stored in RIS.
6. Patients should be registered with the Health Service prior to MDM discussion to enable upload of all clinical documents, such as synoptic reports and MDM summaries to the EMR.
7. MDM reviews of externally generated CTs that are documented using the new synoptic report, should be uploaded to the medical record with the MDM summary documentation.
8. Clear guidelines are needed to support radiologists when issuing a review report for MDM treatment planning purposes on a CT scan that was requested by, and completed for, another provider.
9. To allow completion of the synoptic report, specialist radiologists should be given sufficient notice prior to the MDM to review pancreatic CT imaging.
10. RANZCR (Royal Australian and New Zealand College of Radiology) endorsement of the pancreatic resectability synoptic report template should be pursued.
11. A wider roll out of synoptic reporting using the REDCap platform would require individual assessment of hospital IT capabilities to fully implement, as not all HS have uniform IT capabilities to allow direct send and upload of REDCap reports to EMR.
12. Any further expansion of the pancreatic resectability synoptic reporting project should be managed with a central oversight model and with the use of previously developed tools to ensure consistency

Appendices

A. Governance Meetings and Updates

Pancreatic Resectability Project Steering Group Membership List	Pancreatic Resectability Project Working Group Membership List										
<p>CHARLES PILGRIM (Chair), Surgeon, Alfred ANDREW HAYDON (Deputy Chair), Medical Oncologist, Alfred KAREN BOTTING DH COLIN HORNBY DH MARK GOODWIN Radiologist, Austin ADRIAN FOX Surgeon, Box Hill & St Vincent's ADINA BORSARU Radiologist, Monash SELEENA SHERWELL SMICS KATHERINE SIMONS NEMICS ANNA MACIEJEWSKA SMICS NADIA AYRES NEMICS</p>	<p>CHARLES PILGRIM (Chair) Surgeon, Alfred ANDREW HAYDON (Deputy Chair) Medical Oncologist, Alfred MARK GOODWIN Radiologist, Austin SAMANTHA ELLIS Radiologist, Alfred PHILLIP TRAN RADILOGIST, Western ADRIAN FOX Surgeon, Box Hill & St Vincent's JULIAN CHOI Surgeon, Western JOHN ZALCBERG Oncologist, UGI Registry, AGITG TOM SUTHERLAND Radiologist, St Vincent's ARGANZ HYUN KO Radiologist, Peter Mac MEHRDAD NIKFARJAM Surgeon, Austin/Epworth DAN CROAGH Surgeon, Monash SWEET PING NG Radiation Oncologist, Austin PAUL RILEY Radiologist, CMC, Goulburn Valley Service & Ballarat Health Service ANNA MACIEJEWSKA SMICS NADIA AYRES NEMICS</p>										
History of meetings held	History of meetings held										
<table border="0"> <tr> <td>November 2019</td> <td>July 2020</td> </tr> <tr> <td>February 2020</td> <td>June 2021</td> </tr> <tr> <td>April 2020</td> <td>December 2021</td> </tr> </table>	November 2019	July 2020	February 2020	June 2021	April 2020	December 2021	<table border="0"> <tr> <td>February 2020</td> <td>April 2020</td> </tr> <tr> <td>March 2020</td> <td>May 2020</td> </tr> </table>	February 2020	April 2020	March 2020	May 2020
November 2019	July 2020										
February 2020	June 2021										
April 2020	December 2021										
February 2020	April 2020										
March 2020	May 2020										
History of formal updates	Other project team meetings										
<p>1 Oct 2020 written update in relation to pilot commencement Dec 2020 pilot progress update Mar 2021 Pilot progress first quarter data update 30 Sept 2021 Options Paper presentation</p>	<p>A total of 8 project team meetings, which included attendance by Project Chair, Deputy Chair, and/or Pilot Leads and Project Team from September 2019 to December 2021.</p>										
<p>The Project Team worked in partnership with the UGICR team to conduct the pilot project and develop the synoptic report master template</p>											
<p>JOHN ZALCBERG Head, Cancer Research Program, Public Health and Preventive Medicine, Monash Health JENNIFER HOLLAND Registry Coordinator MADDY QUINN Project Officer GERSHI SAMARASEKARA Project Officer ELYSIA GREENHILL Program Manager BENJAMIN BROWN Data Manager</p>											

B. Synoptic Report

a) Full Synoptic report as it appears in REDCap

Synoptic radiology report pancreatic cancer -pilot

PID 1026

Actions: Download PDF of instrument(s)

VIDEO: Basic data entry

Synoptic Report

Data Access Group: Alfred Health

Editing existing Record ID: XXXXXXXXXX

Record ID 7010-17

Basic Details

Time synoptic report started

* must provide value

11-03-2021 11:37 Now D-M-Y H:M

For patients being reentered from RIS use the time the radiologist commenced the report

URN: *(Enter '99' if patient is not allocated a URN already)*

Hospital: Alfred Health

Surname:

First Name:

Date of Birth: D-M-Y

Sex: Female

Date of CT scan for assessment

* must provide value

20-01-2021 Today D-M-Y

This project relates to CT only. Patients who have had MRI scans ONLY are excluded

Date of synoptic review

* must provide value

28-01-2021 Today D-M-Y

Imaging source

* must provide value

Internal

Refers to pancreatic protocol CT

Biliary stent present on staging scan?

* must provide value

No

plastic or metal

CT Chest scan available?

* must provide value

Yes

Unequivocal distant metastases present?

* must provide value

No

If Yes, classify as 'Unresectable-M'

Appropriate pancreatic cancer imaging protocol?

* must provide value

Yes

Refers to pancreatic imaging only. At least biphasic (pancreatic phase and portal venous phase with slice thickness and reconstructions 3mm or less).

Mass Characteristics	
Mass Visible? <small>* must provide value</small>	<input type="radio"/> <input type="radio"/> Yes <input type="radio"/> No
Mass size (cm)	<input type="text" value="4.3"/> <small>in cm to one decimal place - i.e. 3.2</small>
Mass Location	<input type="checkbox"/> Uncinate process <input checked="" type="checkbox"/> Pancreatic head <input type="checkbox"/> Pancreatic neck <input type="checkbox"/> Pancreatic body <input type="checkbox"/> Pancreatic tail
Mass enhancement pattern	<input type="text" value="Mass hypoattenuating"/> <small>Relative to normal pancreas in pancreatic parenchymal phase</small>
Pancreatic duct cut-off present? <small>* must provide value</small>	<input type="radio"/> <input type="radio"/> Yes <input type="radio"/> No
Bile duct cut-off present? <small>* must provide value</small>	<input type="radio"/> <input type="radio"/> Yes <input type="radio"/> No
Arterial Evaluation	
Superior Mesenteric Artery (SMA)	
Any SMA contact present? <small>* must provide value</small>	<input type="radio"/> <input type="radio"/> No <input type="radio"/> Yes
Coeliac Axis	
Any coeliac axis contact present? <small>* must provide value</small>	<input type="radio"/> <input type="radio"/> Yes <input type="radio"/> No
Coeliac degree of tumour contact	<input type="text" value="Less than 180 degrees"/>
Coeliac focal vessel narrowing or contour irregularity?	<input type="radio"/> <input type="radio"/> No <input type="radio"/> Yes
Common Hepatic Artery (CHA)	
CHA contact present? <small>* must provide value</small>	<input type="radio"/> <input type="radio"/> Yes <input type="radio"/> No
CHA degree of tumour contact	<input type="text" value="180 degrees or more"/>
CHA focal vessel narrowing or contour irregularity?	<input type="radio"/> <input type="radio"/> No <input type="radio"/> Yes
If CHA contact definitely present, is there also contact or irregularity of either the Proper Hepatic Artery or Coeliac Axis?	<input type="radio"/> <input type="radio"/> No <input type="radio"/> Yes
Anatomical arterial variant present? <small>* must provide value</small>	<input checked="" type="checkbox"/> No <input type="checkbox"/> Accessory right hepatic artery <input type="checkbox"/> Replaced right hepatic artery <input type="checkbox"/> Replaced common hepatic artery <input type="checkbox"/> Other
Any aortic tumour contact? <small>* must provide value</small>	<input type="radio"/> <input type="radio"/> No <input type="radio"/> Yes

Venous Evaluation

Main Portal Vein (MPV)

MPV tumour contact

* must provide value

MPV degree of tumour contact

MPV vessel narrowing or contour irregularity

* must provide value

MPV thrombus in vessel?

* must provide value

Superior Mesentric Vein (SMV)

SMV tumour contact

* must provide value

SMV thrombus in vessel?

Lowest level of MPV/SMV involvement relative to inferior border of 3rd part of duodenum

Venous collaterals present?

* must provide value

Additional findings :

Data entered from RIS

Expand

Conclusion and Resectability Status

ANATOMICAL RESECTABILITY STATUS

* **MUST BE COMPLETED** This radiological anatomical resectability status must be entered and it **WILL** be included in the medical record

* must provide value

THE RESECTABILITY LOGIC CALCULATION IS FOR REFERENCE ONLY

This calculation has not been fully 'tested' and **WILL NOT** appear on the medical record or be displayed in the downloaded pdf report.

Anatomical Resectability Calculation

1= Resectable (R)

2= Borderline Resectable - Venous involvement (BR-PV)

3= Borderline Resectable - Arterial involvement (BR-A)

4= Unresectable - Locally Advanced (UR-LA)

5= Unresectable- Metastatic (UR-M)

View equation

b) Synoptic Report as it appears in the local RIS at Alfred Health

Pancreas Cancer Resectability - Synoptic CT Reporting Template

Basic details:

Imaging source \$@<Imaging Source(*refers to pancreatic protocol CT*)>/Internal/External@
 Biliary stent present on staging scan? \$@<Stent(*plastic or metal*)>/Yes/No@
 CT Chest scan available? \$@<CT Chest>/Yes/No@
 Appropriate pancreatic staging imaging protocol? \$@<*Refers to pancreatic imaging only. At least biphasic (pancreatic phase and portal venous phase with reconstructions < 3mm). If "No" do not complete the rest of the form.*>/Yes/No/Unknown@
Reason for inadequate imaging
 Non-biphasic(pancreatic phase and portal venous phase) study \$@<>/No/Yes@
 Axial slices thickness>3mm \$@<>/No/Yes@
 Reconstruction (coronal or sagittal) thickness>3mm \$@<>/No/Yes@
 Axial, Coronal, Sagittal PV phase >3mm \$@<>/No/Yes@
 Other reason for inadequate imaging \$@<Specify Other reason>@
 Do you wish to proceed with the assessment of resectability? \$@<Proceed>/Yes/No@

Distant metastases:

Lung metastases present? \$@<Lung Mets>/Yes/No/Indeterminate@
 Liver metastases present? \$@<Liver mets>/Yes/No/Indeterminate@
 Peritoneal or omental metastases present? \$@<Peritoneal mets>/Yes/No/Indeterminate@
 Ascites present? \$@<Ascites>/Yes/No@
 Bone metastases present? \$@<Bone mets>/Yes/No/Indeterminate@
 Abnormal lymph nodes present? \$@<Abnormal Lymph nodes (*only refers to LNs outside resection margin, short axis diameter*) > 10mm)>/Yes/No@
 Abnormal lymph node locations \$@<Abnormal lymph node locations>/Porta hepatis/Coeliac/Para-aortic/Aortocaval/Retroperitoneal/Other@
 Other metastases present? \$@<Other metastases>/Yes/No/Indeterminate@
 Definite distant metastatic disease? \$@<Definite distant metastatic disease (*Yes = If there are definite lung, liver, peritoneal, bone or other metastases present*)>/Yes/No@

Mass characteristics:

Mass visible? \$@<Mass visible>/Yes/No@
 Mass size \$@<Mass visible (*In cm to one decimal place*)>cm@
 Mass location \$@<Mass location>/Uncinate process/Pancreatic head/Pancreatic neck/Pancreatic body/Pancreatic tail@
 Mass enhancement pattern \$@<Mass enhancement pattern (*Relative to normal pancreas in pancreatic parenchymal phase*)>/Mass hypoattenuating/Mass isoattenuating/Mass hyperattenuating@
 Pancreatic duct cut-off present? \$@<Pancreatic duct cut-off present>/Yes/No@
 Bile duct cut off present? \$@<Bile duct cut off present>/Yes/No@

Arterial evaluation:

Any SMA contact present?	\$@<SMA contact present>/Yes/No@
SMA degree of tumour contact	\$@<SMA degree of tumour contact>/Less than or up to 180 degrees/More than 180 degrees@
SMA focal vessel narrowing or contour irregularity?	\$@<SMA focal vessel>Yes/No@
Contact extension to first SMA branch?	\$@<Contact extension >Yes/No@
Any coeliac axis contact present?	\$@<coeliac axis contact >/Yes/No@
Coeliac degree of tumour contact	\$@<Coeliac degree of tumour contact>/Less than or up to 180 degrees/More than 180 degrees@
Coeliac focal vessel narrowing or contour irregularity?	\$@<Coeliac focal vessel narrowing or contour irregularity>Yes/No@
Common hepatic artery contact present?	\$@<Common hepatic artery contact present>/Yes/No@
CHA degree of tumour contact	\$@<CHA degree of tumour contact>/Less than or up to 180 degrees/More than 180 degrees@
CHA focal vessel narrowing or contour irregularity?	\$@<CHA focal vessel narrowing or contour irregularity>Yes/No@
If CHA contact definitely present, is there also contact or irregularity of either the Proper Hepatic artery or Coeliac axis?	\$@<>/Yes/No@
Anatomical arterial variant present?	\$@<Anatomical arterial variant present>/No/Accessory right hepatic artery/Replaced right hepatic artery/Replaced common hepatic artery/Other@
Any aortic tumour contact?	\$@<Any aortic tumour contact>/Yes/No@

Venous evaluation:

Main portal vein tumour contact	\$@<Main portal vein tumour contact>/Present/Absent@
MPV degree of tumour contact	\$@<MPV degree of tumour contact>/Less than or up to 180 degrees/More than 180 degrees@
MPV vessel narrowing or contour irregularity	\$@<MPV vessel narrowing >/Absent/Present – unilateral narrowing/Present – bilateral narrowing/Present – occlusion@
MPV thrombus in vessel present?	\$@<MPV thrombus in vessel present>/Present/Absent@
Type of MPV thrombus present?	\$@<Type of MPV thrombus present>/Bland/Tumour/Both/None@
SMV tumour contact	\$@<SMV tumour contact>/Present/Absent@
SMV degree of tumour contact	\$@<SMV degree of tumour contact>/Less than or up to 180 degrees/More than 180 degrees@
SMV vessel narrowing or contour irregularity	\$@<SMV vessel narrowing or contour irregularity (including tethering or teardrop)>/Absent/Present-unilateral narrowing/Present-bilateral narrowing/Present – occlusion@
SMV thrombus in vessel present?	\$@<SMV thrombus>/Present/Absent@

Type of SMV thrombus present	\$@<Type of SMV thrombus >/Bland/Tumour/Both@
SMV tumour extension to first jejunal draining vein	\$@<SMV tumour extension to first jejunal draining vein>/Present/Absent@
Lowest level of PV/SMV involvement relative to inferior border of 3 rd part of duodenum	\$@<>/Inferior extent of tumour contact lies above the inferior border of D3/Inferior extent of tumour contact lies below the inferior border of D3@
Venous collaterals present?	\$@<Venous collaterals >/Present/Absent@
Conclusion and Resectability Status:	
Inadequate imaging for staging	\$@<Inadequate imaging for staging>/Yes/No@
Potential confounding biliary stent present?	\$@<Potential confounding biliary stent present>/Yes/No@
Anatomical resectability status	\$@<Anatomical resectability status>/Resectable(R)/ Borderline resectable (BR-PV)/Borderline resectable (BR-A)/Unresectable (Locally advanced – LA)/Unresectable (Metastatic – M)@

C. Post Pilot clinician survey feedback received

Survey questions for Radiologists	
Questions	Responses
What was the standout benefit of using this new synoptic report tool?	<ul style="list-style-type: none"> improved consistency of staging the ease, reduces likelihood of making error/leaving out info standardised definitions and nomenclature so no confusion regarding proposed staging for each patient. If a radiologist doesn't remember the specific details/categories regarding vascular involvement, it is described in the template. quicker and more concise report.
Does your local health service MDM process allow you to complete the report prior to the MDM?	<ul style="list-style-type: none"> Rostering issues. Very late downloads of external images.
How would you rate the complexity of saving the REDCap generated synoptic report to your local health service medical record?	<ul style="list-style-type: none"> not particularly streamlined. Many steps involved but the challenges are likely to be different between various health services
Do you have any other comments in relation to this project?	<ul style="list-style-type: none"> The inbuilt logic to assist in determining resectability is a fantastic addition and I believe will be particularly useful when the template extends to other health services where the radiologists may not see many pancreatic cancers per annum. This will hopefully assist in more accurate staging thereby improving patient's treatment options and outcomes.

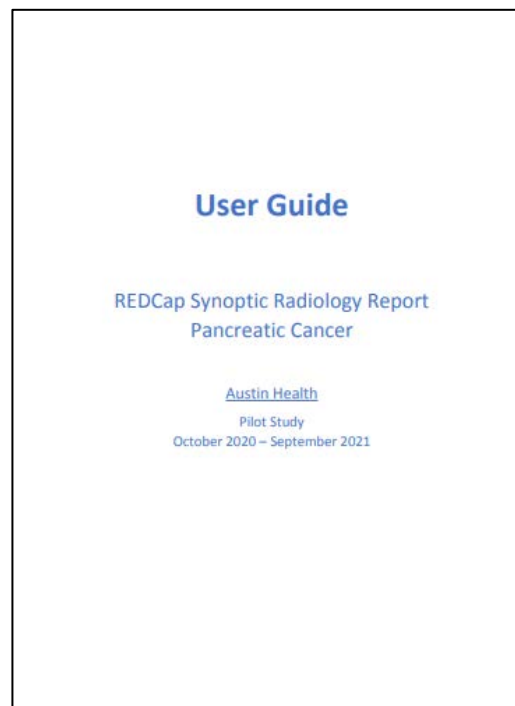
Survey questions for MDM clinicians	
Questions	Responses
Please rate usefulness of synoptic report.	<ul style="list-style-type: none"> very useful. Templated systematic way of describing evaluation. Ensures we don't just assume it has 'been looked at and is not a concern', when actually it hasn't been reviewed in detail. (S) Useful. A summary/overview sentence along with the synoptic report would be useful. It is a bit painful to read the synoptic report line by line without a global understanding of the key findings at the outset e.g. 25mm mass in HOP with venous abutment but no arterial involvement (S)
Following MDM, the actual synoptic report is uploaded to EMR. Did you refer to the document following MDM?	<ul style="list-style-type: none"> Always look at the scan reports of my patients (MO) Information in relation to management of pancreatic patients (RO) Always reviewed prior to clinic and operations if came to that. Another set of eyes to identify aberrant arterial anatomy that is not always reported in the usual report is useful (S) Refresh memory of findings when seeing the patient in clinic (S) Check resectability and explain strategies to patients (S) No need as I attend MDM (S) to check results prior to patient outpatient consultation and discussions regarding surgery and surgical risks (S) To plan what treatment intent the patient will have (MO)

Survey questions for MDM clinicians	
Questions	Responses
The resectability status is documented in the MDM outcome summary. Have you referred to the resectability status found in the record following the MDM?	<ul style="list-style-type: none"> Rx and Mx intent (RO) Anatomical/radiological resectability does not take into account biochemistry etc. Both are required. (S) Refresh memory of plan prior to seeing patient (S) Outpatient review of the patient (S) to review MDM findings for patients during outpatient consultations (S)
Do you have any other comments in relation to this project?	<ul style="list-style-type: none"> Great MDM (RO) For Alfred scanned patients we use a template in the RIS which is then manually retrieved and placed on Redcap. Requires 2 steps. The layout of the RIS generated template is difficult to read. Needs work (R) Enjoyed seeing the development. Hope it continues (S) Well done. Great initiative to improve consistency in reporting and (hopefully) reduce variability in treatment decisions (S) REDCap tool is very quick and easy to use (R) I think it's an excellent initiative (S) Nice project. Making us aware that many patients don't have adequate imaging and documentation of resectability status (S) Excellent project to standardize reporting. Helps with decisions and in particular audit / research. (S) Has been very useful for improving surgical planning and patient care (S)
S = surgeon R = radiologist MO = medical oncologist RO = radiation oncologist	

D. Communication and Engagement

Four newsletter issues were produced as part of the project and distributed to more than 90 stakeholders in the pancreatic community in the state.

A dedicated training manual for use of the synoptic report in REDCap was developed for radiologists and surgeons.



E. Other Project learnings

Other learnings from pancreatic resectability project	
1.	Preliminary data shows that the rate of Borderline Resectable disease identified at MDM prior to the introduction of the synoptic report was in the order of 8% increasing to 14%, with the use of the new synoptic tool.
2.	Dedicated MDM software with standard dropdown menus supports consistent recording of resectability, otherwise documentation is variable.
3.	An automated process for transferring the report PDF from REDCap to HS EMR is needed to ensure the report is consistently uploaded.
4.	Variability exists in the functionality/capability of RIS platforms across health services in the state (not all systems allow addition of custom templates).
5.	MDM documentation needs to clearly distinguish between the anatomical resectability status versus the overall status (the anatomical resectability is the 'A' in the overall status description of ABC - anatomical, biological, conditional).
6.	A quality handover between registrars performing the scribe roll in MDMs is imperative in ensuring documentation of resectability remains consistent. The process also needs to be championed by the Chair of the MDM.
7.	Having a visible copy of the International Guidelines criteria available to the radiologist when completing the report was noted as helpful by participating clinicians.
8.	RIS data is generally not download-able. Data needs to be re-entered into REDCap to support central storage of data. This represents a small percentage of cases.
9.	RIS does not support a background logic calculation function.
10.	RIS synoptic reports may not print to a visually appealing layout. This can make reading/interpreting the results difficult.
11.	HS run various versions of REDCap and therefore functionality can vary between HS. Some versions of REDCap allow direct email of a PDF of a completed report to Health Information Services (HIS).
12.	The International Guidelines contain some 'grey' areas which makes designing a stable background logic calculation more complex.
13.	Sending patient data off site from a health service to a secure database requires ethics approval. The rules governing transmitting data vary by individual HS.
14.	Most key HS in Victoria with HPB MDMs have local REDCap databases and already contribute pancreatic cancer data to the UGICR (ethics approvals are in place, data is collected by UGICR auditors)
15.	If patients are not registered prior to listing on an MDM agenda the likelihood of uploading the MDM summary and actual synoptic report diminish with time.
16.	If imaging is poor or substandard, it is important to note this in MDM summaries to monitor the overall quality of images presented for review at meetings.
17.	The availability of dedicated administrative staff to support MDM processes varies between HS.

Other learnings from pancreatic resectability project

18. VCR does not currently collect radiology data or resectability status but have indicated they may be interested in doing so in the future. In the interim the UGICR are providing this important function.
19. Radiologists reported benefit in having the logic calculation to support decision making.

References

References				
No.	Author/s	Article name/ Origin	Year	Publication
1	Dr Susan Williamson, Conjoint Professor David Goldstein, Associate Professor Andrew Barbour, Associate Professor Jaswinder Samra, Dr Koroush Haghighi, Dr Mehrad Nikfarjam and Professor James Kench. Co-authored by Dr Payal Saxena.	Definition of surgical standards for pancreatic cancer: A consensus statement by the Australasian Gastro-Intestinal Trials Group	2015	Australasian Gastro-Intestinal Trials Group
2	Shuji Isaji, Shugo Mizuno, John A. Windsor, Claudio Bassi, Carlos Fernandez-del Castillo, Thilo Hackert, Aoi Hayasaki, Matthew H.G. Katz, Sun-Whe Kim, Masashi Kishiwada, Hirohisa Kitagawa, Christoph W. Michalski, Christopher L. Wolfgang.	International consensus on definition and criteria of borderline resectable pancreatic ductal adenocarcinoma 2017	2017	Pancreatology Journal
3	Dhakshinamoorthy Ganeshan, Phuong-Anh Thi Duong, Linda Probyn, Leon Lenchik, Tatum A. McArthur, Michele Retrouvey, Emily H. Ghobadi, Stephane L. Desouches, David Pastel, Isaac R. Francis	Structured Reporting in Radiology	2018 (Jan)	Radiology Research Alliance, Academic Radiology, Vol 25, No 1.
4	Cancer Imaging Program, Cancer Care Ontario.	Synoptic Radiology Reporting: Methodology for a Systemized Approach to Clinical Checklist Development	2014	Cancer Care Ontario, Clinical Checklist Development Governance
5	Mahmoud M. Al-Hawary, Isaac R. Francis, et al.	Pancreatic Ductal Adenocarcinoma Radiology Reporting Template: Consensus Statement of the Society of Abdominal Radiology and the American Pancreatic Association	2014 (Jan)	Radiological Society of North America (RSNA) - Radiology: Volume 270: No 1
6	Seung Baek Hong, Seung Soo Lee, Jin Hee Kim, Hyoung Jung Kim, Jae Hoe Byun, Seung Mo Hong, Ki-Byung Song, Song Cheol Ki	Pancreatic Cancer CT: Prediction of Resectability according to NCCN Criteria	2018	RSNA - Radiology: Volume 289: No 3
7	Robert C Gandy, Andrew P Barbour, Jaswinder Samra, Mehrdad Nikfarjam, Koroush Haghighi, James G Kench, Payal Saxena, David Goldstein	Refining the care of patients with pancreatic cancer: the AGITG Pancreatic Cancer Workshop consensus	2016	The Medical Journal of Australia 2016; 204 (11)

References				
No.	Author/s	Article name/ Origin	Year	Publication
8	Beleù A., Calabrese A., Rizzo G., Capelli P., Bellini N., Caloggero S., et al.	Preoperative imaging evaluation after downstaging of pancreatic ductal adenocarcinoma: A multi-center study.	2019	Cancers. 2019 Feb 25;11(2):267.
9	Harris P.A., Taylor R., Thielke R., Payne J., Gonzalez N. & Conde J.G	Research electronic data capture (REDCap) - A metadata-driven methodology and workflow process for providing translational research informatics support	2009	J Biomed Inform. 2009 Apr;42(2):377-81.
10	Joo I., Lee J.M., Lee E.S., Son J-Y., Lee D.H., Ahn S.J., et al.	Preoperative CT classification of the resectability of pancreatic cancer: Interobserver agreement.	2019	Radiology. 2019 Nov;293(2):343–9.
11	National Comprehensive Cancer Network	National Comprehensive Cancer Network (NCCN) Clinical Practice Guidelines in Oncology. Pancreatic Adenocarcinoma.	2016	National Comprehensive Cancer Network, Version 1. 2016.
12	Loizou L, Albiin N, Ansorge C, Andersson M, Segersvärd R, Leidner B, et al	Computed tomography staging of pancreatic cancer: A validation study addressing interobserver agreement.	2013	Pancreatology. 2013 Nov;13(6):570–5.
13	Loizou L., Duran C.V., Axelsson E., Andersson M., Keussen I., Strinholm J, et al.	Radiological assessment of local resectability status in patients with pancreatic cancer: Inter-reader agreement and reader performance in two different classification systems.	2018	Eur J Radiol. 2018 Sept; 106:69–76.
14	Pilgrim, C.H.C., te Marvelde, L., Stuart, E., Croagh, D., Deutscher, D., Nikfarjam, M., Lee, B., and Christophi, C.	(2020), Population-based analysis of treatment patterns and outcomes for pancreas cancer in Victoria.	2020	ANZ Journal of Surgery. doi:10.1111/ans.15721
15	Wittel U.A., Lubgan D., Ghadimi M., Belyaev O., Uhl W., Bechstein W.O., et al.	Consensus in determining the resectability of locally progressed pancreatic ductal adenocarcinoma – results of the Conko-007 multicenter trial.	2019	BMC Cancer [Internet]. 2019 Dec [cited 2020 Jan 13];19(1). Available from: https://bmccancer.biomedcentral.com/articles/10.1186/s12885-019-6148-5

Reviewed Websites
www.cancervic.org.au/for-health-professionals/optimal-care-pathways
www.cancer.org.au/about-cancer/types-of-cancer/pancreatic-cancer.html
www.ugicr.org.au
www.wehi.edu.au/people/peter-gibbs
www.gicancer.org.au
www.arganz.org/